

Ultrasonography Assessment of Repaired Median Nerve

Masoud Yavari¹, Soraya Shahrokh Shahraki², Ali Tabrizi^{1,3}*, Afshin Mohammadi⁴

¹ Department of Hand and Microsurgery, Panzdahe Khordad Hospital, Shahid Beheshti University of Medical Sciences, Tehran, Iran

² Department of Plastic Surgery, Panzdahe Khordad Hospital, Shahid Beheshti University of Medical Sciences, Tehran, Iran

³ Department of Orthopedics, Imam Khomeini hospital, Urmia University of Medical Sciences, Urmia, Iran

⁴ Department of Radiology, School of Medicine, Imam Khomeini Hospital, Urmia University of Medical Sciences, Urmia, Iran

* **Corresponding Author:** Ali Tabrizi, Department of Orthopedics, Imam Khomeini hospital, Urmia University of Medical Sciences, Urmia, Iran. **Email:** Ali.tab.ms@gmail.com

Received November 20, 2020; **Accepted** July 02, 2021; **Online Published** July 02, 2021

Abstract

Background: Traumatic peripheral nerve injuries (PNIs) caused by penetrating and lacerated trauma are among the most prevalent microsurgical injuries. Post-treatment follow-up and prognosis of patients undergoing repair are often based on clinical examinations and electrodiagnostic findings. Therefore, a reliable, inexpensive, useful, and rapidly accessible diagnostic method is necessary during the patient's follow-up.

Objectives: This study aimed to assess the relationship between ultrasound imaging and treatment outcomes in patients with median peripheral nerve injury.

Methods: In this cohort study, 21 eligible patients with symptoms of acute median nerve injury (MNI) caused by penetrating trauma in microsurgery were studied from June 2018 to June 2019. The patients underwent ultrasonography three months after repair and were followed up for at least nine months. The outcomes of the treatment were compared with those obtained six months after ultrasonography.

Results: In all studied patients, mean thicknesses of the repaired nerve on the distal and the proximal sides were 2.58 ± 0.51 and 2.51 ± 0.61 mm², respectively; 12 cases (57.1%) recovered very well nine months after surgery and in nine cases (42.9%) no nerve recovery was observed based on clinical electromyography (EMG) examinations and nerve conduction velocity (NCV). The amount of neuroma formed at the repair site was lower in well-recovered patients (1.5 ± 0.4 mm³) than those with no recovery (4.9 ± 1.5 mm³). No re-rupture was observed at the repair site. Each group underwent two-four repairs of flexor tendons.

Conclusion: Ultrasound can be used as an effective and non-invasive method for assessment of PNI and follow-up of reconstructive surgery.

Keywords: Median nerve, Neuroma, Ultrasound.

Introduction

Peripheral Nerve Injury (PNI) can occur nowadays for a variety of reasons. Penetration, fractures, crush injuries, and stab wounds are the most common causes of PNI and have a prevalence of about 2.8% among trauma patients. Taking a proper history, performing physical and neurological examinations, nerve conduction velocity tests, and electromyography are considered as the proper methods in the diagnosis of PNI. Electrodiagnostic tests as the gold standard in the diagnosis of PNI, can determine the site of a nerve lesion.¹ Electrodiagnostic tests, however, cannot provide clear information about the type of injury, serves for the severed nerve imaging, detection of the presence or absence of neuroma, and evaluation of tissue scarring around the lesion for surgical intervention guiding and planning. Therefore, physicians currently need a reliable, inexpensive, useful, and rapidly accessible diagnostic method during the

follow-up period.¹⁻⁴ There have been many advances in imaging techniques, such as Magnetic Resonance Imaging (MRI), to examine peripheral nerves. Although MRI is a preferred method for the assessment of soft tissue injury, it cannot show small and minor nerves as well as the amount of severed nerve.³ Several advantages are associated with ultrasound for the diagnose of MNI (must be defined), including cost-effectiveness, quick detection ability, access to long parts of the nerve pathway, few contraindications, portability, non-invasiveness, and easy access to information, which is not obtainable by the electrophysiological or other tests. Surgeons can also use ultrasound to diagnose and evaluate pre-and postoperative patients with nerve injury caused by trauma, neoplasia, infection, or crushes.⁴ Peer et al. reported a high potential of ultrasound in the follow-up of patients undergoing peripheral nerve repair.⁵

Objectives

Therefore, this study aimed to evaluate postoperative repair of median nerves and the potential of ultrasound in the diagnosis of nerve regeneration.

Materials and Methods

In a cohort study, 21 patients with symptoms of acute sharp cut MNI and complete rupture (caused by penetrating trauma or laceration of the wrist) from Jan 2018 to Jun 2019 who referred to the Hand and Microsurgery Department were included in the study. Based on nerve recovery, the patients were divided into two groups (with nerve recovery versus no evidence of nerve function). Inclusion criteria were age ($18 < \text{age} < 65$ years), lack of congenital neurological disorder, lack of diabetes and other systemic diseases with an increased possibility of neuropathy, no previous history of wrist nerve surgery and wrist deformity, and absence of cervical discopathy. All eligible patients were selected and followed up under clinical examination and electrodiagnostic tests at intervals of 3, 6, and 9 months. The analyzed electrodiagnostic information included a combination of the action potential amplitudes recorded from the electrodes in electromyography (EMG). The number of simultaneously injured flexor tendons and the distance of MNI from the flexor retinaculum were recorded in the patients. Patients with two neurological injuries (including median and ulnar), vascular injury, crushed hand, and simultaneous fractures of the forearm and wrist bones were excluded from the study. Evaluated patients were only those with isolated MNI and simultaneous flexor tendon injury in the wrist. All patients were recovered immediately within 6-12 h after injury. For nerve repair, end to end neurorrhaphy was performed with epineurial by 8-0 monofilament nylon sutures. In the case of flexor tendon injury in Zone V (proximal to carpal tunnel) simultaneously, the standard Kessler core stitch method was performed and 0-3 sutures were used for flexor tendons repair. The posterior plaster splint was placed in the wrist flexion position of 20-45°. The rehabilitation program was the same for all patients. After 3 months of repair, ultrasound was performed by a Supersonic Ultimate device with a 5-18 SL line converter connected to an ultrasound system. The patients were oriented according to the injured area. Special attention was also paid to the stable placement of the injured limb by

support pads. In order to move the probe and increase the accuracy, a layer of gel was applied to the injured site. Ultrasound was accomplished at the injury site at least 10 cm above and 5 cm below the injury site. Examined parameters were the form, echo pattern, diameter, and volume of the neuroma, the overall integrity of the nerve and nerve bundles, perineurium, epineurium, and peripheral tissues of the median nerves (**Figure-1**, **Figure-2**). All ultrasounds were performed by an experienced sonographer who was unaware of the results of clinical examinations and electrodiagnostic tests. The rate of sensory recovery was determined using Semmes-Weinstein monofilament test in patients at the last follow-up. So that in patients, perception of cutaneous pressure threshold, reflecting re-innervations of peripheral targets was checked.⁶ Based on the average regeneration rate of 1 mm/day in humans, we followed patients for at least 9 months.⁷ Patients' final recovery was determined based on the both clinical and EMG information.

All surgical repairs were executed by a surgical team under a microscope device. After obtaining written consent from patients, this study was performed under the supervision of the Ethics Committee of the Urmia University of Medical Sciences (ethical code: 97-06-63-1856).

In this study, the distribution of postoperative clinical and ultrasound variables was investigated in all patients. Mean volumes of the neuroma between individuals, neuronal reversal, and neurological disorders were evaluated by Mann-Whitney U, and Fisher's exact test was used in the case of qualitative variables with a significance level of P-value < 0.05. Data were analyzed using SPSS software (Version 17/win).

Results

The age of all patients was in the range of 20-55 years with a mean age of 31.47 ± 8.68 years. Of the 21 patients studied, 16 (76.2%) cases were male and 5 (23.8%) were female. In all patients, the mean thicknesses of the repaired nerve on the distal and the proximal sides were 2.58 ± 0.51 and 2.51 ± 0.61 mm², respectively. Of the total patients, 12 cases (57.1%) recovered well 9 months after surgery, and 9 cases (42.9%) had no nerve recovery based on the clinical examinations.

According to the analysis, the volume of neuroma formed at the repair site was lower in well-recovered patients (1.5 ± 0.4 mm³) than those with no recovery (4.9 ± 1.5 mm³).

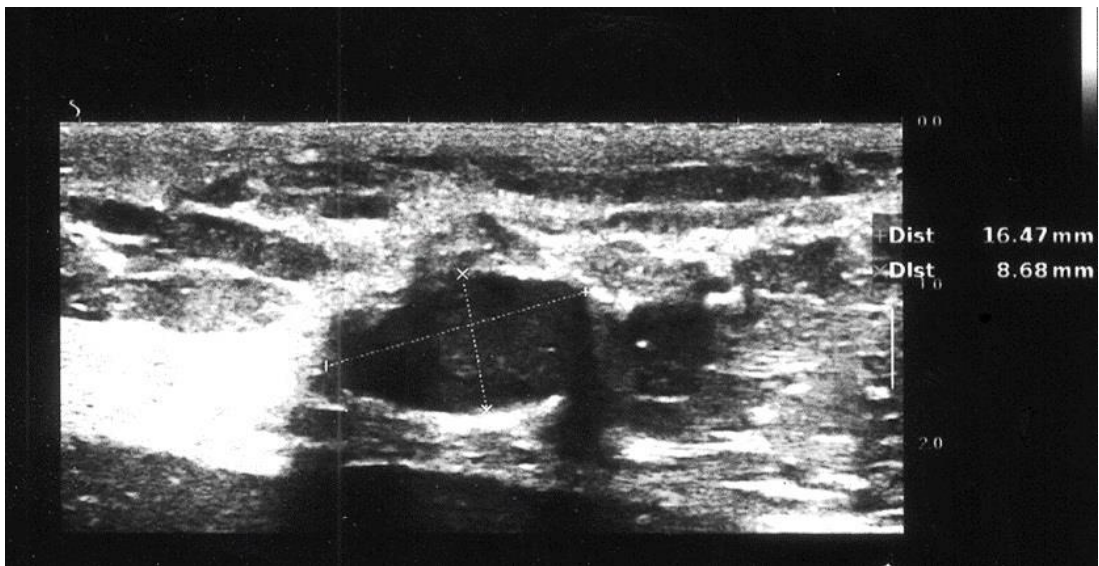


Figure-1. Transverse ultrasonography shows a bizarre shape hypodense nodule at the repaired site of the Median nerve after surgical repair of previous trauma

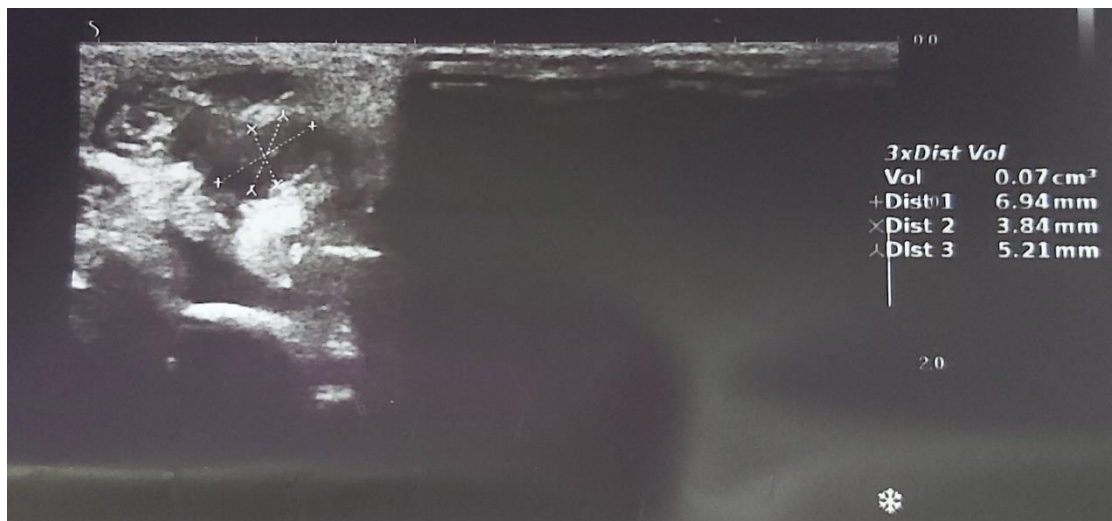


Figure-2. Determination of neuroma volume at the site of nerve repair

No re-rupture case was observed at the repair site. According to [Table-1](#), there were significant differences between the two groups concerning the neuroma volume. Each group underwent at least two up to four repairs of flexor tendons. A statistically significant difference was found in the recovery frequency of patients in whom the repair occurred at a further distance from the carpal tunnel.

Discussion

Based on our findings, there was a significant relationship in the neuroma volume in ultrasonographic of median nerve recovery after repair. However, there is no consensus on the use of ultrasound findings in the follow-up of the patients. The patients with acute peripheral nerve trauma and nerve rupture are traditionally followed up post-treatment through

clinical examinations and electrodiagnostic findings (EMG & NCV). Nerve function recovery often depends on various factors. Among them the type and severity of nerve injury and repair quality can be considered as the factors affecting the process of nerve function restoration.¹

Therefore, affected patients have some degrees of nerve injury after initial repair and the lack of proper nerve function makes it difficult to make decisions about these patients. There is no criterion for re-intervention and surgical revision.^{5,8}

Decisions are often made based on clinical examinations, surgeons' clinical experience and surgeons' skills.

Electrodiagnostic findings are often unreliable for several months and clinical examinations vary in different nerves (sensory and motor).

Table-1. Ultrasound findings of the nerve and neuroma volume at the site of repair 3 and 9 months after surgery in terms of recovery rate

Variable	Good recovery N=12	Without recovery N=9	P value
Mean in proximal mm ² after 3 months	2.2±0.5	2.9±0.5	0.8
Mean in distal mm ² after 3 months	2.3±0.3	2.8±0.4	0.2
Neuroma volume mm ³ after 3 months	2.5±0.4	4.9±1.5	< 0.001
Injuries in carpal tunnel entrance	3 (25%)	0	
Injury at a distance of more than 1.5 cm to carpal tunnel	6 (50%)	3 (33.3%)	0.04
Injury at a distance of less than 1.5 cm to carpal tunnel	3 (25%)	6 (66.6%)	
Mean in proximal mm ² after 9 months	2.1±0.2	2.9±0.7	0.6
Mean in distal mm ² after 9 months	2.2±0.1	2.9±0.6	0.4
Neuroma volume mm ³ after 9 months	2.3±0.5	4.8±1.4	< 0.001

Briefly, after peripheral nerve repair, there is no criterion for the assessment of a repaired nerve condition, and hence ultrasound can provide reliable findings for the physician. After the initial nerve restoration, ultrasound can clearly show the formation of a neuroma, nerve discontinuity, and pressure on the nerve due to the surrounding scar tissue. Determination of nerve continuity after the initial repair is almost impossible by clinical examination, and ultrasound is a minimally invasive, easy, and accessible procedure.^{5,8}

Epineural epineurium integrity is a basic prerequisite to achieve proper recovery of neural function in patients undergoing epineurial sutures. Therefore, ultrasound can provide reliable data from restored peripheral nerves. Nerve trunk continuity and intact epineurium, particularly in patients undergoing epineural (fascicular) restoration, indicate a suitable neural function restoration.^{4,5} In Peer et al. (2003) study, of 20 patients with peripheral nerve injury, 9 patients showed proper recovery, and 11 patients had postoperative neurological dysfunction. The volume of formed neuroma was consistent with reoperation findings and the lack of nerve continuity on ultrasound in cases of no nerve recovery.⁵ In our study, 21 patients were followed up, but nerve function recovery was not observed in 9 patients. Consistent with the findings of Peer et al. (2003)⁵ study, ultrasound was helpful in diagnosing the adhesion and volume of a neuroma in median nerve recovery after repaired in our study. In another study, Peer et al. (2001) studied 18 patients with PNI using high-resolution sonography and observed increased nerve thickness and hypovacogenic swelling of fascicles suggestive of diffuse axonal swelling, which were associated with restored nerve recovery.⁹ The continuity of median nerve (selected in our study) was confirmed in all patients undergoing primary peripheral

nerve repair, and the thickness before and after the repair site was not associated with nerve recovery.³ However, the volume of neuroma formed in patients without nerve recovery was significantly higher than in other patients. The term trauma is often used for swelling after acute nerve trauma caused by forming a mass of unorganized axon fibers and the growth of non-neural connective tissue, which could be due to an improper and untechnical repair. In Coraci et al. (2015) study, no correlation was reported between the neuroma volume and nerve function after acute nerve trauma in the absence of closed nerve injury, but a 5-fold increase in its volume relative to the nerve diameter was associated with a poor prognosis of nerve recovery.¹⁰ Similarly, our cases with high volumes of neuroma at the repair site were associated with poor nerve function outcomes. Also, good performance results were not observed in cases where the injury was near (<1.5 cm) to the carpal tunnel. This is one of the reasons for severe scarring and pressure on the restored nerve because carpal tunnel release was not performed in these cases, and they underwent only nerve repair. Based on Coraci et al. study (2015),¹⁰ the neuroma volume and ultrasonographic evaluation could not predict the prognosis of patients with peripheral nerve injuries. It seems that many of these injuries are associated with deep incisions, simultaneous tendon and soft tissue injuries. Thus adhesion occurs with a wide range. The skill of the person performing the ultrasound plays a key role in its performance. So that performing ultrasound by a specialist in musculoskeletal ultrasound has a very important role in the results. In our study, this procedure for all subjects was performed by a person who had seen a course of musculoskeletal ultrasound. High-resolution ultrasound is an important tool in the diagnosis, management, and follow-

up of PNI with high sensitivity and specificity in the diagnosis. The ultrasound can be used to successfully determine the accurate location of the injury site, nerve thickness, and neuroma volume in all patients with peripheral nerve injuries.¹¹ In Zaidmen et al. study, the comparison between MRI and ultrasonography revealed that the latter had a high sensitivity (93% vs. 67%) and the both methods showed an almost similar specificity of 86%, but the ultrasound implementation in PNIs showed a high efficiency and easiness compared to MRI.¹² According to a review study by Alaqeel et al., results of recovery after PNI repair in patients who were followed up by ultrasound were close to those of our study.¹³ In China, Lu et al. evaluated the role of ultrasound in the diagnosis of PNI in 34 people and followed them up after the surgical repair. They reported that ultrasound failed to identify only one out of 59 cases of PNI and recommended the use of ultrasound as a valuable method in the management of PNI treatment in their initial assessment.³ Consistent with the findings of Lu et al. study, in our study, the use of ultrasound was effective in diagnosing adhesions and determining the volume of neuroma in the follow-up period of patients.

Conclusions

The results of this study indicated that ultrasound can be used as a suitable method during follow-up of restored peripheral nerves, and hence can be applied in the determination of functional prognosis and recovery of restored nerves.

Acknowledgments

This study was financially supported by Urmia University of Medical sciences.

Authors' Contribution

All authors pass the four criteria for authorship contribution based on the International Committee of Medical Journal Editors (ICMJE) recommendations.

Conflict of Interests

There is no conflict of interest to be reported.

Funding/Support

The authors received no financial funding or support for the research.

References

1. Wang C-H, Hsu Y-C, Chen S-G, Chen T-M, Chen S-L. The value of Presurgical Ultrasonography in Chronic Median Nerve Injury of the Palm: Case Report and Review of the Literature. *Journal of Medical Sciences*. 2010;30(3):119-22.
2. Toros T, Karabay N, Llzaksar K, Sugun T, Kayalar M, Bal E. Evaluation of peripheral nerves of the upper limb with ultrasonography: a comparison of ultrasonographic examination and the intra-operative findings. *The Journal of bone and joint surgery British*. 2009;91(6):762-5. doi:10.1302/0301-620X.91B6.22284
3. Lu M, Wang Y, Yue L, Chiu J, He F, Wu X, et al. Follow-up evaluation with ultrasonography of peripheral nerve injuries after an earthquake. *Neural regeneration research*. 2014;9(6):582. doi:10.4103/1673-5374.130095
4. Ali ZS, Pisapia JM, Ma TS, Zager EL, Heuer GG, Khoury V. Ultrasonographic evaluation of peripheral nerves. *World neurosurgery*. 2016;85:333-9. doi:10.1016/j.wneu.2015.10.005
5. Peer S, Harp C, Willeit J, Piza-Katzer H, Bodner G. Sonographic evaluation of primary peripheral nerve repair. *Journal of ultrasound in medicine*. 2003;22(12):1317-22. doi:10.7863/jum.2003.22.12.1317
6. Khambati FA, Shetty VP, Ghate SD, Capadia GD. Sensitivity and specificity of nerve palpation, monofilament testing and voluntary muscle testing in detecting peripheral nerve abnormality, using nerve conduction studies as gold standard; a study in 357 patients. *Lepr Rev*. 2009;80(1):34-50. doi:10.47276/lr.80.1.34
7. Emamhadi M, Behzadnia H, Andalib S. Long-term surgical outcome of median nerve injuries. *Formos J Surg* 2019;52:71-5.
8. Bodner G, Huber B, Schwabegger A, Lutz M, Waldenberger P. Sonographic detection of radial nerve entrapment within a humerus fracture. *J Ultrasound Med* 1999; 18:703-706. doi:10.7863/jum.1999.18.10.703
9. Peer S, Bodner G, Meirer R, Willeit J, Piza-Katzer H. Examination of postoperative peripheral nerve lesions with high-resolution sonography. *AJR Am J Roentgenol*. 2001;177(2):415-419. doi:10.2214/ajr.177.2.1770415
10. Coraci D, Pazzaglia C, Doneddu PE, et al. Post-traumatic neuroma due to closed nerve injury. Is recovery after peripheral nerve trauma related to ultrasonographic neuroma size?. *Clin Neurol Neurosurg*. 2015;139:314-318. doi:10.1016/j.clineuro.2015.10.034
11. Chen K-H, Lee K-F, Hsu H-C, Huang W-C, Hsiao K-Y, Fang K-M. The role of high-resolution ultrasound in the diagnosis of a traumatic neuroma in an injured median nerve. *American journal of physical medicine & rehabilitation*. 2009;88(9):771-4. doi:10.1097/PHM.0b013e3181b332ef
12. Zaidman CM, Seelig MJ, Baker JC, Mackinnon SE, Pestronk A. Detection of peripheral nerve pathology: comparison of ultrasound and MRI. *Neurology*. 2013;80(18):1634-40. doi:10.1212/WNL.0b013e3182904f3f
13. Alaqeel A, Alshomer F. High Resolution Ultrasound in the Evaluation and Management of Traumatic Peripheral Nerve Injuries: Review of the Literature. *Oman Med J* (2014);29(5):314-319. doi:10.5001/omj.2014.86