

Assessments and Treatment of Gunshot Injuries to the Penis

Mousa Asadi ¹, Hasan Goodarzi ², Sadrollah Mahmoodi ^{2*}

¹ Nephrology and Urology Research Center, Baqiyatallah University of Medical Sciences, Tehran, Iran

² Trauma Research Center, Baqiyatallah University of Medical Sciences, Tehran, Iran

* **Corresponding Author:** Sadrollah Mahmoodi, Trauma Research Center, Baqiyatallah University of Medical Sciences, Tehran, Iran.

Email: sadrollah.mahmoudi@gmail.com

Received January 14, 2021; **Accepted** April 01, 2021; **Online Published** April 01, 2021

Abstract

Background: Gunshot wound injuries to penile are relatively infrequent.

Objectives: This study aimed at reviewing the patterns of gunshot injuries to the penile and their treatments.

Methods: In November 2019, PubMed (MEDLINE), Scopus, Embase, ISI web of sciences and Google Scholar databases were searched for finding relevant studies. For this reason, various meshes and keywords were used to search including wound/injury, genitalia/genitourinary, Gunshot/war/explosion/firearm/military, penile/penis, scrotum, and urethral.

Results: Of the five included studies, three studies were related to civilian gunshot injuries and two studies were related to war-injury. The average age of patients was in the range of 28-31 years old. The major gunshot penile injuries were Corporotomy, Corpus cavernosum, superficial penile wounds, and urethral injury. The most frequent concomitant damages were injuries to adjacent anatomies, including thigh injury, scrotal/testicular, abdominal organs, bladder, and rectum. There are several surgical procedures depending on the degree of gunshot penile injuries such as surgical exploration, closing the residual penile stump of a partly amputated penis, penile degloving, penoscrotal approach, simple suturing, hemostatic suturing of Buck's fascia and skin, and surgical re-anastomosis or total replacement with phallic reconstruction.

Conclusion: Penile gunshot injuries often are concomitant with other severe injuries in adjacent anatomies, which have a negative impact on the mortality of victims. For the management of these cases, it is essential to evaluate the length and size of and type of weapons.

Keywords: Gunshot, Penis, Injuries.

Introduction

Prompt precise diagnosis and proper therapy of penile gunshot injuries are crucial for achieving the best outcomes.¹⁻

⁴ Also, mid managing injuries and healing penile performance, the cosmetic outcome is an essential issue for the patients and surgeons.⁵⁻⁷ Gunshot injuries to the genitourinary relatively to other injuries are uncommon. The majority series of these patients have been reported following wars or in massive metropolitan regions.^{8,9}

However, these damages have the potential to affect the ensuing quality of life for victims.¹⁰ Various suitable therapeutic approaches are used to treat all kinds of penile gunshot injuries.¹¹ The choice of surgical approaches are depended on the type, severity, and location of penile injuries.

Despite appropriate treatment and good rehabilitation of external genital gunshot wounds, there is the possibility of occurring various complications such as erectile dysfunction, urethral stricture, and infertility in these victims.¹²⁻¹⁸

Genital injuries have been commonly reported in wars or large cities. However, there are substantial differences

between military and civilian gunshot injuries.^{19,20}

Objectives

In this study, we tried to review the major articles about gunshot wound injuries to the penile in order to help clinicians and patients to have a better understanding of these injuries and choose the best therapeutic procedure.

Materials and Methods

Search strategy

In November 2019, PubMed (MEDLINE), Scopus, Embase, ISI web of sciences and Google Scholar databases were searched for finding relevant studies. For this reason, various meshes and keywords were used to search including wound/injury, Gunshot/war/explosion/firearm/military, genitalia/genitourinary, penile/penis, scrotum, and urethral. Moreover, an appropriate combination of these terminologies was used for searching. Searches were performed by two independent expert reviewers to validate the scientific quality of the paper. Then, after eliminating duplicate records using endnote software, the search results

were again screened by the two reviewers by the titles and abstracts of all related records.

Inclusion criteria

We included only studies that considered patients with gunshot penile injuries as their main results.

Data screening

Two reviewers independently assessed full-texts of the related articles, and then the inclusion criteria and disagreements were solved by discussion with a third reviewer.

Data collection

Results were presented regarding studies' years, patients' age, penis injuries, associated injuries, and previous treatment history. Two expert reviewers independently extracted data from the full-text articles using a tested extraction sheet, and disagreements were solved by discussion with a third reviewer.

Results

In this study, 157 records were selected from the search of databases. After removing duplicates and abstract screening, 15 records were eligible for full-text screening. The full-text screening resulted in 5 articles that were eligible for the final review (Figure-1).¹⁹⁻²³ Table-1 presents the summary of the included articles in the final review.

Epidemiology

Genitourinary injuries have reported in 0.5–4.2% of all war wounds.¹⁻³ These injuries included less than 10% of all trauma wounds. The penile injury accounts for about 10% - 16% of total urinary tract injuries.³⁻⁵ The average age of the participants with penile injuries with gunshot was in the range 28-31 years old.¹⁹⁻²³ Of the five studies,¹⁹⁻²³ three studies²¹⁻²³ were related to civilian gunshot injuries and two studies were related to war-injury. In a study, it has been reported that the source of civilian gunshot injuries was associated with criminal reasons in 43%, unknown in 50% of patients and accidents in 7% of all cases.²²

In a study related to war-injury, it has been reported that the sourced of injuries in Civilians was 64% and Iraqi military personnel was 36%.¹⁹ The injuries were caused by an improvised explosive device (56%) and individual firearms (44%). Another similar study reported that the causes of penile injuries were gunshots (62%) and blasts (31%).^{19,20}

Penis and associated injuries

The most common penile injuries with gunshot wounds

were Corporotomy, Corpus cavernosum, superficial penile wounds and urethral injury. The most frequent associated injuries were to adjacent anatomies including as thigh, scrotal/testicular, abdominal organs, bladder, and rectum.¹⁹⁻²³

Evaluation

Physical examination, palpable corporal tissue, expanding hematoma, or uncontrolled bleeding from a wound involving the penile shaft for primary evaluation should be performed. Retrograde urethrogram should be conducted in all cases with deep penile or penoscrotal wounds unless the superficial wounds. For the examination of associated damages, further diagnosis facilities, such as ultrasound of scrotal contents, angiography, and CTS should be used.¹⁹⁻²³

Treatments

There were several surgical procedures depending on the degree of gunshot penile injuries such as surgical exploration (Corpus cavernosum only, debridement of glans or skin, Corpus, Urethra only and cavernosum and urethra), closing the residual penile stump of a partly amputated penis, penile degloving, penoscrotal approach, simple suturing, hemostatic suturing of Buck's fascia and skin, and surgical re-anastomosis or total replacement with phallic reconstruction. If necessary, to properly manage potentially fatal injuries such as vascular or intra-abdominal injuries, the management of patients with genital injuries may be prolonged.¹⁰

Preoperative evaluation of injuries should not be prolonged and its time in the arrived patients requiring surgery in the operating room was about 2 hours following the presentation.¹⁹⁻²³

Although the surgical procedure to penile wounds depends on the situation of injury; a lateral approach or sub-coronal degloving can present proper performance for most penis injuries.²¹

Penis injuries should be treated, following debridement of necrotic tissue, by suturing the tunica albuginea and approach of Buck's fascia. Subsequent closing the penis skin, a Foley catheter should be fixed, an elastic pressure dressing is utilized and the penis is then taped to the below abdomen.²³ Penis injuries and bulbar urethra should be managed by primary suturing or resection and anastomosis, with urethral catheter drainage for 2 to 3 weeks post operation.²⁰

Injury to the posterior urethra should be repaired by initial realignment and by a suprapubic cystostomy.²²

A study²⁰ showed that the most penile injuries related to war were managed by debridement and treatment of damaged corporal parties and/or damaged urethra moreover to the suprapubic cystostomy (20.7%) (Table-1).

Treatment of gunshot to the exterior genitalia in a war environment demands consideration of tissue protection while organizing related surgical methods.¹⁹ Treatment should not only be considered for curing normal voiding, but erectile function and the cosmetic aspect of the penis should also be considered.^{19,20}

Penis exploration was recommended for all injuries such as corpora cavernosa or urethra. The corpora cavernosa and spongiosum visualization is obtained through effectively degloving the penile with a subcoronal circumscribing surgery. Also, other studies have suggested exploration by a

penoscrotal incision. The purposes of surgical procedures are to obtain hemostasis, restore the integrity of injured formations, restore physiologic function, and cosmesis.¹²⁻¹⁴

The artificial erection should be created using injecting saline into the cavernosa provides for the evaluation of corporeal integrity through exploration.²²

Circumcision during exploration may be considered to decrease after surgery edema and patient discomfort and complications. In this regard, antibiotic irrigation was used for the prevention of any infectious complications. Full-thickness skin grafting may be required to perform the complete penile repair method. In the complex injuries, consulting of plastic surgeons and psychiatrists to the management of these cases was also recommended.²¹⁻²³

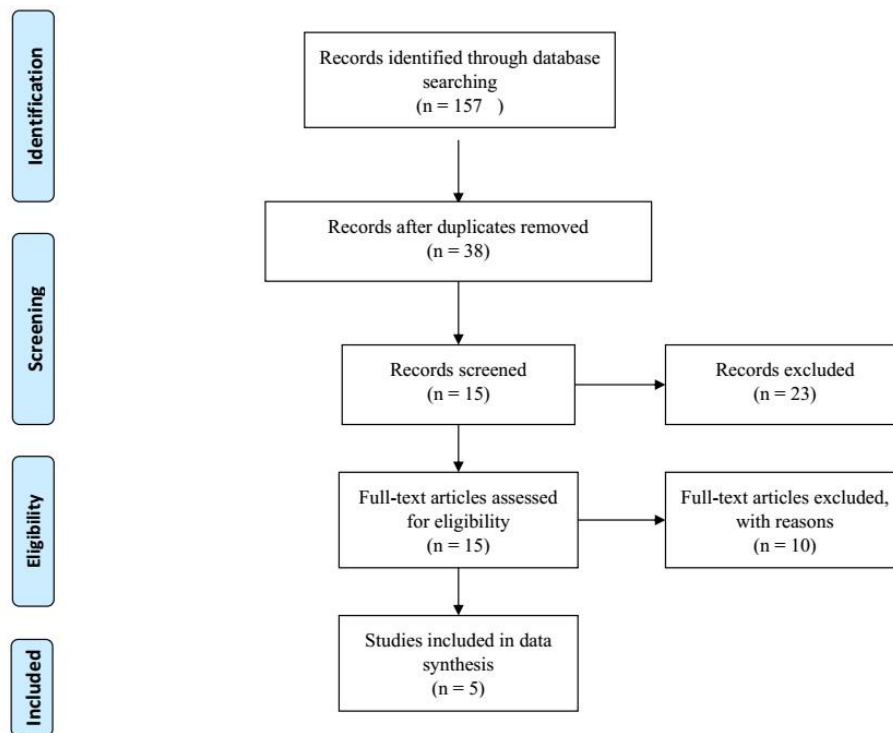


Figure-1. PRISMA flow diagram

Discussion

Gunshot wounds to the penile; either in the metropolitan area or military battlefield are quite infrequent as regarding to other injuries.²⁻⁵ Previous studies showed that the most of the patients are young (with an average age between 28 and 31 years).¹⁹⁻²³

In the current study, the major penile injuries with gunshots were Corporotomy, Corpus cavernosum, superficial penile wounds and urethral injury. Moreover, the major concomitant damages were injuries to adjacent anatomies, such as thigh injury, scrotal/testicular, abdominal

organs, bladder, rectum, and vascular injuries.¹⁹⁻²³ In these patients, penile injuries were related to the size and the velocity of the weapons.⁷⁻¹⁰

In this study, we included five studies investigating patients with penile injuries in civilian and military situations. The differences of injuries can be described by the variations in shooting ranges and differences of weapons. For the management of these damages, it is essential to evaluate the length and size of the injury and the type of the used weapons.¹⁷⁻²⁰

Partial or minor penile injuries can be treated nonoperatively in some of the patients with sustain penile

injuries.²² Closing the residual penile stump of a partly amputated penis, surgical exploration (debridement of glans or skin, Corpus cavernosum only, Corpus cavernosum and urethra, and Urethra only), penile degloving, simple suturing, penoscrotal approach, hemostatic suturing of Buck's fascia and skin, and surgical re-anastomosis or total replacement with phallic reconstruction are considered for the management of severe penile injuries.^{19,20} Nonetheless, the management of penile injuries can be carefully delayed for suitable treatment of any life-threatening related damages.^{10,19}

In the patients of urethral injuries, initial surgical treatment

is a possible, even in the patients of large urethral defects; the operation procedure of surgical reconstruction should be examined in two steps.²⁰ In erectile dysfunction cases, in addition to urologists, psychiatrists, psychotherapists, and plastic surgeons should participate in the treatment of these cases.¹²⁻¹⁵

However, the records available may only indicate the "tip of the iceberg" and does not represent a massive accident in all penile injuries. Genital injuries are uncommon in men due to the high protection of this area and the high degree of these injuries.²¹⁻²³ There are differences between military and civilian gunshot injuries.

Table-1. Characteristics of the included studies (authors' name, years, number, penile injuries, associated injuries and treatments)

Authors	Penis injuries	Associated injuries	Treatments
Cerwinka et al. (2009) ²²	Penis only (10), Skin only (45%), Corpus cavernosum (35), Urethra (24%), Glans (19%).	Associated injuries (90), Commonly lower extremities (69%) or the scrotum (skin (31%), Testis (14%) and Spermatic cord (7%)) (52%), Abdomen (17),	Surgical exploration (72%). penile degloving (45%), local exploration (41%), penoscrotal approach (14%). Surgical repair (Debridement of glans or skin (48%), Corpus cavernosum only (24%), Corpus cavernosum and urethra, (21%) and Urethra only (7%)
Kunkle et al. (2008) ²¹	Corporotomy only (49.2%), superficial penile wounds (32%), corporotomy and urethral injury (14%) and urethral injury only (4.7%).	Associated injuries overall 84%, thigh injury (74%), scrotal/testicular injury (55.5%), isolated penile injury (16%), intra-abdominal injury (10), vascular injury (8%), femur fracture (8%) and sciatic nerve injury (2%).	Retrograde urethrogram (79%) Primary urethral repair 8 patients with urethral injury versus 4 patients with urinary diversion by means of suprapubic cystotomy.
Cavalcanti et al. (2006) ²³	Corpus cavernosum (30.2%), testicular and Corpus cavernosum (23.2%), urethra and Corpus cavernosum (32.6%), superficial structures (14%).	Thigh (34.8%), bone lesion (13.9%), intra-abdominal lesion (23.2%), vascular lesion (6.9%) and absence of extragenital lesions (55.8%).	Surgical exploration (95.3%) and conservative treatment (4.7%)
Al-Azzawi et al. (2014) ¹⁹	Penile injuries (53.3%), 15 bulbar urethra (33.3%) and posterior urethra (13.3%).	Scrotum and scrotal (60%), bladder (40%), rectum (44%), other abdominal organs (67%), major blood vessels (18%) and fractures of the pelvic bones (47%). Nine (20%) died associated with major vascular injury.	Debridement of necrotic tissue, suturing the tunica albuginea and approximation of Buck's fascia. After closing the penile skin, a Foley catheter was fixed, an elastic pressure dressing was applied and the penis was then taped to the lower abdomen. penectomy (3 patients with grade 5). Direct suturing or resection and anastomosis with urethral catheter drainage for 2-3 weeks (patients with penile and bulbar urethra). Suprapubic cystostomy (5 patients with posterior urethra). Perineal repair (urethral strictures/distraction).
Etabbal et al (2018) ²⁰	Glanular laceration (13.7%), corporal bodies injury (68.9%) and urethral injury (34.5%).	Scrotal (48.3%), testicular (31%), abdominal (31%), chest (14%), skeletal (14%), head (11%), and vascular (3%) injuries. Amputation of lower extremities (3%), amputation of one leg (7%), and fractured femur (3%)	Debridement and hemostatic suturing of Buck's fascia and skin (28%), Simple suturing (14%). Debridement and hemostatic suturing of lacerated glans (14%) or debridement and reconstruction of injured corporal bodies and/or injured urethra in addition to the suprapubic cystostomy (20.7%), Debridement and hemostatic suturing of the tunica albuginea and Buck's fascia (3%). The initial and meticulous reconstruction of the corporal bodies with the realignment of fragile urethra over an 18-F silicone catheter with suprapubic urinary diversion (14%), Partial penectomy with skin grafting due to extensive skin loss (7%).

Army injuries are affected by high-velocity weapons, which cause higher tissue damage, and often need a urinary diversion and staged treatment. A previous study reported that the source of civilian gunshot injuries was unstated in 50% of cases and was related to criminal causes in 43% and accidents in 7%.²² The frequently criminal experience of cases with civilian gunshot wounds to the penis results in the weaker follow-up than in a military group.^{19,20}

Overall, the investigation of long-term complications and results in these cases is usually inadequate due to the low numbers of cases prepared for long-lasting follow-up.¹⁵ Nevertheless, studies have reported complications following penile gunshot injuries concerning potency, erectile dysfunction, and cosmesis. Further investigations are required to prospectively assess procedures for the treatment of gunshot penile injuries. Also, standardized surveys could be utilized in future studies to assess erectile function and patients' satisfaction following penile gunshot wounds.

This study had several notable limitations: First, only English published articles were reviewed. However, several databases were utilized to reduce the bias of not selecting relevant articles. Second, there were various studies reporting genital injuries and in some cases they only reported penile injuries as a part of their data. We included only studies that considered patients with gunshot penile injuries as their main results.

Conclusions

Penile gunshot injuries often are concomitant with other severe injuries in adjacent anatomies those themselves negatively affected on morbidity and mortality of victims. For the management of these cases, it is essential to evaluate the length and size of the injuries, as well as the type of weapons.

Acknowledgments

None.

Authors' Contribution

All authors pass the four criteria for authorship contribution based on the International Committee of Medical Journal Editors (ICMJE) recommendations.

Conflict of Interests

None.

Funding/Support

None.

References

1. Marshall DF. Urogenital wounds in an evacuation hospital. *J Urol*. 1946;55:119-132. doi:10.1016/S0022-5347(17)69886-0
2. Busch FM, Chenault OW, Zinner NR, Clarke BG. Urological aspects of Vietnam War injuries. *The Journal of urology*. 1967 Apr;97(4):763-5. doi:10.1016/S0022-5347(17)63114-8
3. Salvatierra O, Rigdon WO, Norris DM, Brady TW. Vietnam experience with 252 urological war injuries. *The Journal of urology*. 1969; 101(4): 615-20. doi:10.1016/S0022-5347(17)62390-5
4. Hudolin T, Hudolin I. Surgical management of urogenital injuries at a war hospital in Bosnia Herzegovina, 1992-1995. *J Urol*. 2003; 169:1357-1359. doi:10.1097/01.ju.0000051220.77880.64
5. Phonsombat S, Master VA, McAninch JW. Penetrating external genital trauma: a 30-year single institution experience. *J Urol* 2008;180:192-6. doi:10.1016/j.juro.2008.03.041
6. Ahmed A, Mbibu NH. Aetiology and management of injuries to male external genitalia in Nigeria. *Injury* 2008;39:128-33. doi:10.1016/j.injury.2007.02.039
7. Dogo HM, Ibrahim AG, Gana YL. Missile injuries to the external genitalia: a five-year experience in Maiduguri, North Eastern Nigeria. *Int J Res Med Sci* 2016;4:2964-6. doi:10.18203/2320-6012.ijrms20161986
8. Selikowitz SM. Penetrating high-velocity genitourinary injuries. Part II: Urethral, lower tract, and genital wounds. *Urology*. 1977;9: 493-499. doi:10.1016/0090-4295(77)90239-4
9. Mohr AM, Pham AM, Lavery RF, Sifri Z, Bargman V, Livingston DH. Management of trauma to the male external genitalia: the usefulness of American Association for the Surgery of Trauma organ injury scales. *The Journal of urology*. 2003;170(6):2311-5. doi:10.1097/01.ju.0000089241.71369.6a
10. Waxman S, Beekley A, Morey A, Soderdahl D. Penetrating trauma to the external genitalia in Operation Iraqi Freedom. *Int J Impot Res* 2009; 21: 145-8. doi:10.1038/ijir.2008.59
11. Settles GS. High-speed imaging of shock waves, explosions and gunshots. *Am Sci*. 2006;94:22-31. doi:10.1511/2006.57.22
12. Morey AF, Metro MJ, Carney KJ, Miller KS, McAninch JW. Consensus on genitourinary trauma: external genitalia. *BJU Int*. 2004;94:507-15. doi:10.1111/j.1464-410X.2004.04993.x
13. Perovic SV, Djinojic RP, Bumbasirevic MZ, Santucci RA, Djordjevic ML, Kourbatov D. Severe penile injuries: a problem of severity and reconstruction. *BJU Int* 2009;104:676-87. doi:10.1111/j.1464-410X.2008.08343.x
14. Monga M, Moreno T, Hellstrom WJ. Gunshot wounds to the male genitalia. *J Trauma*. 1995;38:855-858. doi:10.1097/00005373-199506000-00003
15. Mahamat AM, Sougui S, Ouchemi C, Ngaringuem O, Jalloh M, Niang L, et al. Severe external genitalia lesion by firearm: a case report. *Open J Urol*. 2015;5:188-91. doi:10.4236/oju.2015.510030
16. Cline KJ, Mata JA, Venable DD, et al. Penetrating trauma to the male external genitalia. *J Trauma*. 1998;44:492-494. doi:10.1097/00005373-199803000-00011
17. Gomez RG, Castanheira AC, McAninch JW. Gunshot wounds to the male external genitalia. *J Urol*. 1993;150:1147-1149. doi:10.1016/S0022-5347(17)35710-5
18. Miles BJ, Poffenberger RJ, Farah RN, et al. Management of penile gunshot wounds. *Urology*. 1990;36:318-321. doi:10.1016/0090-4295(90)80237
19. Husmann DA, Boone TB, Wilson WT. Management of low velocity gunshot wounds to the anterior urethra: the role of primary repair versus urinary diversion alone. *J Urol*. 1993;150:70-72. doi:10.1016/S0022-5347(17)35399-5
20. Al-Azzawi IS, Koraitim MM. Urethral and penile war injuries: The experience from civil violence in Iraq. *Arab journal of urology*. 2014;12(2):149-54. doi:10.1016/j.aju.2013.11.002
21. Etabbal AM, Hussain FF, Benkhadoura MO, Banni AM. War-related penile injuries in Libya: Single-institution experience. *Arab journal of urology*. 2018;16(2):250-6. doi:10.1016/j.aju.2018.01.005
22. Kunkle DA, Lebed BD, Mydlo JH, Pontari MA. Evaluation and management of gunshot wounds of the penis: 20-year experience at an urban trauma center. *Journal of Trauma and Acute Care Surgery*. 2008 Apr 1;64(4):1038-42. doi:10.1097/TA.0b013e3180342036
23. Cerwinka WH, Block NL. Civilian gunshot injuries of the penis: the Miami experience. *Urology*. 2009;73(4):877-80. doi:10.1016/j.urol.2008.10.057
24. Cavalcanti AG, Krambeck R, Araujo A, Manes CH, Favorito LA. Penile lesion from gunshot wound: a 43-case experience. *International braz j urol*. 2006;32(1):56-63. doi:10.1590/S1677-55382006000100009