

Cubital Tunnel Syndrome: An Entrapment Neuropathy Which May Arise from Vascular Malformation

Mohammadreza Emamhadi ¹, Shahrokh Yousefzadeh-Chabok ^{2,3}, Alireza Mehrvarz ⁴, Sasan Andalib ^{3, 5 *}

¹ Brachial Plexus and Peripheral Nerve Injury Center, Guilan University of Medical Sciences, Rasht, Iran

² Guilan Road Trauma Research Center, Poursina Hospital, School of Medicine, Guilan University of Medical Sciences, Rasht, Iran

³ Neuroscience Research Center, Department of Neurosurgery, Poursina Hospital, Guilan University of Medical Sciences, Rasht, Iran

⁴ Department of Pathology, Golsar Hospital, Rasht, Iran

⁵ Research Unit of Clinical Physiology and Nuclear Medicine, Department of Nuclear Medicine, Odense University Hospital, Faculty of Health Sciences, University of Southern Denmark, Odense, Denmark

* **Corresponding Author:** Neuroscience Research Center, Department of Neurosurgery, Poursina Hospital, Guilan University of Medical Sciences, Rasht, Iran. Email: andalib@gums.ac.ir

Received June 17, 2019; Accepted August 28, 2019; Online Published November 20, 2019

Abstract

Vascular malformation as a cause of cubital tunnel syndrome has not yet been reported. Cubital tunnel syndrome (CuTS), the most common entrapment neuropathy of the ulnar nerve at elbow level, is also the second most common entrapment neuropathy in the upper extremity, regardless of carpal tunnel syndrome. Here, we report CuTS due to vascular malformation in a 63-year-old woman. The ulnar nerve at the distal part of tunnel was markedly compressed. There was no connection between the lesion and the ulnar nerve. The diagnosis was made by using histopathology, and thereafter the lesion was fully resected. Pain in her ring and little fingers disappeared one month after resection of the malformation.

Keywords: Cubital Tunnel Syndrome, Ulnar Nerve, Vascular Malformation.

Introduction

Cubital tunnel syndrome (CuTS) stems from ulnar nerve entrapment and is considered a major cause of hand dysfunction (1-3). The elbow is the most common location of ulnar nerve compression (4) between the olecranon and the medial epicondyle (Figure 1). The roof of this tunnel is formed by a retinaculum called Osborne's ligament.

The discomfort and neurological deficits in this syndrome result commonly from ulnar nerve compression at multiple sites involving the cubital tunnel, medial epicondyle, deep flexor aponeurosis, arcade of Struthers, and medial intermuscular septum (1-3, 5-8).

The most important risk factors of CuTS are diabetes mellitus, prolonged elbow flexion, and obesity (7,8). Surgical and conservative therapeutic approaches are applied according to the signs, symptoms, and severity of CuTS (8).

Physiological compression occurs during elbow flexion. During elbow flexion at 45 degrees, Osborne's ligament buckles 5 mm, causing narrowing of the tunnel. Excessive or repetitive jobs as in cashier work, prolonged elbow flexion such as immobilization of an arm subsequent to fracture, or

upper arm or shoulder dislocation lead to the nerve being stretched and compressed in the cubital tunnel. Compression may also result from masses in the tunnel, including ganglions, perineural cyst, paraosteal lipomas, bursitis or synovitis, or osteophytes. Compression has rarely been due to the presence of the accessory muscle of anconeus epitrochlearis (5,7).

Pressure on the ulnar nerve can result in a direct or indirect decrease in the blood supply to the nerve, leading to peripheral nerve entrapment syndrome (9). At the elbow, the superior and inferior ulnar collateral arteries and the posterior ulnar recurrent artery are the ulnar nerve's main blood suppliers. The superior ulnar collateral artery leads to the brachial artery. It enters the medial intermuscular septum, goes down to the triceps brachii medial head surface in between the olecranon and medial epicondyle along with the ulnar nerve, and ends beneath the flexor carpi ulnaris while anastomosing with the inferior ulnar collateral and posterior ulnar recurrent. The periarticular arterial anastomoses, which makes part of the blood supply to the elbow joint, is created by the superior ulnar collateral artery.

The blood supply to the ulnar nerve and anterior transposition at a suitable distance of the ulnar nerve are important factors in anterior transposition of the vascularized ulnar nerve (9).

Here, we present a case of CuTS due to vascular malformation in the cubital tunnel

Case presentation

A 63-year-old woman who was a retired teacher referred to our center complaining of right upper limb pain originating from the elbow and radiating to the medial side of her hand along with paresthesia and decreased sensation for 6 months. She was unable to sleep due to the pain. Palpation of the ulnar nerve on the medial elbow elicited radiating pain and numbness distally from the elbow. The patient claimed a sensory deficit in the fifth digit and in the right ulnar side of the fourth digit. Rheumatologic and endocrine diseases, hereditary neuropathy, and traumatic injury were not observed in the patient. Neurological examination showed a positive Tinel sign. Sensory examination showed sensory failure to pinprick and light touch in the ring and little fingers. Atrophy was seen in the first dorsal interosseous muscle. There was also weakness in the intrinsic muscles innervated by ulnar nerve. Froment's sign was positive. Electrodiagnostic examination revealed that the right ulnar nerve motor conduction velocity was slow compared with the other side. X-rays of the elbow were also taken and were negative for bone pathology. Since conservative treatment had been started before admission but failed to improve her condition, the patient underwent surgery.

Surgical technique and findings

The ulnar nerve was exposed in the proximal to the cubital tunnel and traced distally by cutting the roof of the tunnel. On the distal side of the tunnel, a cord-like mass parallel to the nerve (Figure 2) was found that was compressing the nerve in the narrowed tunnel. A solid red-purple mass extended from medial epicondyle to origin of two head of flexor carpi ulnaris muscle. The mass was resected en bloc and sent for pathology. Finally, subcutaneous anterior transposition was done for the ulnar nerve. The patient was thereafter splinted, and early range of motion of the elbow to avoid stiff elbow and scarring was commenced. After 3 weeks, exercises were started under the guidance of a physical therapist for strengthening the thumb, finger, wrist, and elbow flexions, and activating shoulder. One month after surgery, the patient's pain was relieved, but paresthesia

remained. Sensory deficit was recovered after three months, but considerable motor recovery was not seen at the nine-month follow-up. Pathology results revealed vascular channels with thickened tortuous walls and irregular outlines favoring vascular malformation (Figure-3).

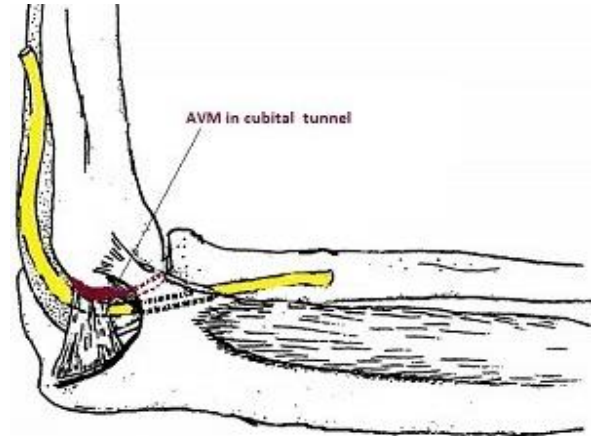


Figure-1. Position of ulnar nerve at elbow

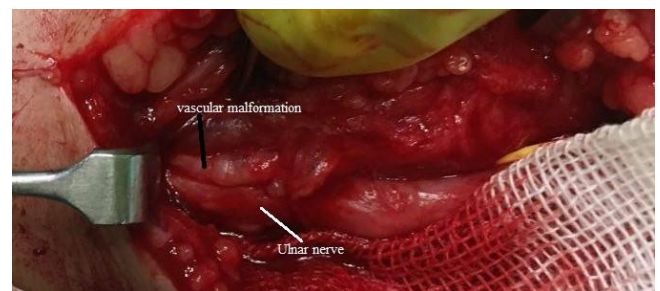

Figure-2. Mass next to ulnar nerve

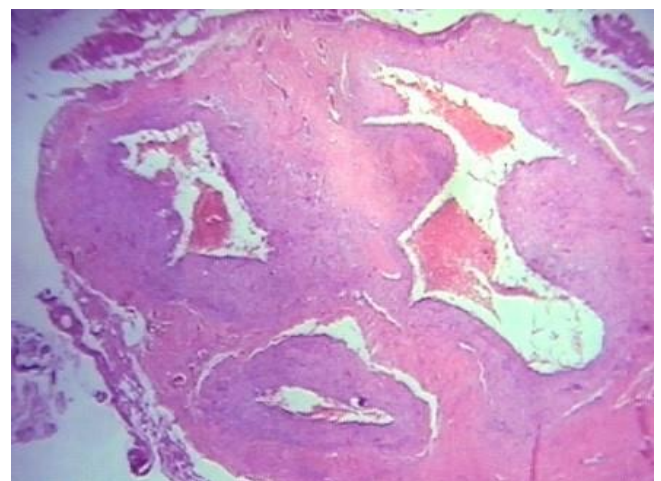


Figure-3. Pathology of mass resected

Discussion

CuTS is a very challenging condition. A differential diagnosis is essential for management of this syndrome. With the presence of a mass in the cubital tunnel including a broad spectrum of benign lesions, ganglion cyst (10), perineural cyst (7), Schwannoma (1), and neoplasms can occur. The

cause of CuTS is well-documented, but vascular malformation has not been reported as a cause of this syndrome (11). A few reports of vascular malformation in a tendon sheath exist, in contrast to such a malformation in the cubital tunnel. Torre (12) reported a thrombosed distal ulnar artery aneurysm and digital emboli of the hand in a young male patient followed by resection of the aneurysm as well as microvascular interposition vein grafting. Thrombosis of the dorsal interosseous artery aneurysm is prevalent and can be linked to various degrees of ischemia (13). Cassileth et al. reported an 8-year-old girl with a capillary vascular malformation in the vinculum of the flexor tendon sheath (14). Hill et al. reported a case of tenosynovitis with a vascular malformation of the flexor tendon. Moreover, pain, compression neuropathies, altered distal thermoregulation, and functional symptoms can be present on adjacent nerves (15). Schonauer et al. reported a rare localized thrombosed vascular malformation in the flexor tendon sheath of the left index finger that was treated by surgery (16). It is believed that vascular malformation should be completely resected with or without microvascular reconstruction, while taking care of adjacent nerves and preventing blood loss and distal limb ischemia (17). Although there are several reports of vascular malformation in the hand, no vascular malformation has been reported as a cause of CuTS. In our case, the ulnar nerve was adjacent to the olecranon bursa and markedly compressed; however, there was no connection between the lesion and the ulnar nerve. We suggest that such a lesion is surgically resected as soon as possible to improve the symptoms of CuTS. Hemangiomas may result from the vascular tissue of the tendon synovium of extensors (18,19) or flexors (20) of the hand. If tendons are invaded, they must be resected with the lesion (18). The ulnar nerve in the deep surface of the flexor carpi ulnaris at the distal end of the cubital tunnel is supplied with nutrition by the branches of the posterior ulnar recurrent artery.

Repeated trauma to this artery or overhead activities like throwing were likely to be the cause of a vascular injury triggering CuTS in our case. Preoperative MRI would be helpful in evaluating the cause of CuTS.

Conclusions

In conclusion, vascular malformation is a very rare cause of CuTS. To obviate the detrimental symptoms of CuTS, the vein should be resected. Early surgical treatment is recommended in CuTS due to vascular malformation.

Acknowledgments

None.

Authors' Contribution

All authors pass the four criteria for authorship contribution based on the International Committee of Medical Journal Editors (ICMJE) recommendations.

Conflict of Interests

The authors declared no potential conflict of interests with respect to the research, authorship, and/or publication of this article.

Funding/Support

The authors received no financial funding or support for the research.

References

1. Liu MT, Lee JT, Wang CH, Lin YC, Chou CH. Cubital Tunnel Syndrome Caused by Ulnar Nerve Schwannoma in a Patient with Diabetic Sensorimotor Polyneuropathy. *Acta neurologica Taiwanica*. 2016;25(2):60-4.
2. Middleton SD, Anakwe RE. A 37-year-old man with numbness in the hand. *CMAJ : Canadian Medical Association journal = journal de l'Association medicale canadienne*. 2015;187(8):593-5.
3. Citisli V, Kocaoglu M, Gocmen S, Korucu M. Unusual presentation of multiple nerve entrapment: a case report. *The Pan African medical journal*. 2014;19:283.
4. Emamhadi M, Emamhadi A, Andalib S. Intramuscular compared with subcutaneous transposition for surgery in cubital tunnel syndrome. *The Annals of The Royal College of Surgeons of England*. 2017;99(8):653-7.
5. Uscetin I, Bingol D, Ozkaya O, Orman C, Akan M. Ulnar nerve compression at the elbow caused by the epitrochleoanconeus muscle: a case report and surgical approach. *Turkish neurosurgery*. 2014; 24(2):266-71.
6. Illes JD, Johnson TL. Chiropractic management of a patient with ulnar nerve compression symptoms: a case report. *Journal of Chiropractic Medicine*. 2013;12(2):66-73.
7. Bayrakli F, Kurtuncu M, Karaarslan E, Ozgen S. Perineural cyst presenting like cubital tunnel syndrome. *European spine journal : official publication of the European Spine Society, the European Spinal Deformity Society, and the European Section of the Cervical Spine Research Society*. 2012;21 Suppl 4:S387-9.
8. Cutts S. Cubital tunnel syndrome. *Postgraduate Medical Journal*. 2007;83(975):28-31.
9. Li M-x-l, He Q, Hu Z-l, Chen S-h, Lv Y-c, Liu Z-h, et al. Applied anatomical study of the vascularized ulnar nerve and its blood supply for cubital tunnel syndrome at the elbow region. *Neural Regeneration Research*. 2015;10(1):141-5.
10. Tong J, Xu B, Dong Z, Liu J, Zhang C, Gu Y. Cubital tunnel syndrome caused by ganglion cysts: a review of 59 cases. *Acta neurochirurgica*. 2017;159(7):1265-71.
11. Wojewnik B, Bindra R. Cubital tunnel syndrome — Review of current literature on causes, diagnosis and treatment. *Journal of Hand and Microsurgery*. 2009;1(2):76-81.
12. Torre J. Ulnar artery aneurysm with digital ischemia. *Vascular Medicine*. 1999;4(3):143-5.
13. O'Farrell DA, Cannon DP, Nunley JA. Digital ischemia associated with a thrombosed aneurysm of the dorsal interosseous artery. A case report. *The Journal of bone and joint surgery American volume*. 1997;79(3):441-3.

14. Cassileth LB, Chang B. Vascular malformation within the flexor tendon sheath. *The Journal of hand surgery*. 2003;28(1):153-6.
15. Hill FC, Yuen A, Ramakrishnan A. Vascular malformation of the flexor tendon presenting as tenosynovitis. *Hand (New York, NY)*. 2012;7(2):200-3.
16. Schonauer F, Nele G, La Rusca I. Thrombosed vascular malformation within the flexor tendon sheath of the index finger in the palm. *Case reports in plastic surgery & hand surgery*. 2015;2(3-4):60-2.
17. Ek ET, Suh N, Carlson MG. Vascular anomalies of the hand and wrist. *The Journal of the American Academy of Orthopaedic Surgeons*. 2014;22(6):352-60.
18. Waddell GF. A haemangioma involving tendons. *The Journal of bone and joint surgery British volume*. 1967;49(1):138-41.
19. Prosperi L, Prosperi P. [Angioma of the sheath of the EDC and EPL tendons of the thumb (clinical and diagnostic considerations on a case)]. *La Chirurgia degli organi di movimento*. 1980;66(2):267-9.
20. Rico AA, Holguin PH, Gonzalez IG, Coba JM. Flexor tendon synovial sheath haemangioma mimicking subacute tenosynovitis. *Journal of hand surgery (Edinburgh, Scotland)*. 1994;19(6):704-5.