

Pain Management in a Case of Severe Electrocution Injury and Resultant Quadruple Amputation

Shigong Guo *, Munim Moiz, David Henderson Slater

Oxford Centre for Enablement, Nuffield Orthopaedic Centre, Oxford, UK

Corresponding Author: Shigong Guo, Oxford Centre for Enablement, Nuffield Orthopaedic Centre, Oxford, UK.

Email: shigong@doctors.org.uk

Received June 8, 2019; Accepted August 28, 2019; Online Published November 24, 2019

Abstract

Background: A 33-year-old patient presented to the Oxford Centre for Enablement for rehabilitation following severe electrical burn injuries requiring bilateral below elbow amputations, right below knee amputation and a left midfoot amputation.

Specific issues: Chronic pain at the amputation sites as well as phantom limb initially proved challenging to manage medically however were eventually controlled with careful consideration of analgesic regimens. Pain was measured using the Numeric Pain Rating Scale. A likely attributing cause for the pain was peripheral neuropathy.

Management: A combination of neuropathic agents and opioids helped to control pain. These analgesic included amitriptyline, gabapentin, pregabalin, tramadol and morphine in various regimens. Paracetamol and ibuprofen were also used.

Implications: Rigorous search strategies were created which interrogated the MEDLINE, EMBASE, CINAHL, PsycINFO databases for studies reporting limb pain management in electrocution injuries. A total of 841 studies were found with 583 screened after removal of duplicates. No RCTs could be identified investigating limb pain management in electrical injuries. Case reports and case series have described various treatment options including nerve blocks, neuropathic analgesia, physiotherapy, botulinum toxin, fracture fixation and even the use of Virtual Reality headsets. We discuss this available evidence. No consensus exists as to the optimum management approach of pain in such patients. From our experience with this patient we suggest that a multi-modal analgesic approach is likely to be needed in such patients and should therefore be considered. Level 1 research into pain management in electrocution injuries is required.

Keywords: Pain, Analgesia, Amputation.

Introduction

The incidence of non-fatal electrical injuries of the severity described in this case (resulting in amputations) is difficult to estimate world-wide. Data from the United States seems to suggest an incidence rate of non-fatal electrical injuries to be between 0.2-3 per 10,000 full time workers between 2003-2012.¹ It appears that as electrical injuries of the severity described in this case are infrequently seen, there is little consensus on the management of pain in these types of patients. We found our approach to pain management in a patient with severe electrical injuries necessitating amputation to be effective and believe this approach may prove useful if others encounter patients of this type, whilst more substantive better-quality evidence is awaited.

Case presentation

A 33-year-old Caucasian man was working on a roof in December 2016 when a pole he was carrying came into contact with a 33-kilovolt overhead cable. He sustained severe electrical burns to both hands and legs. The patient

underwent bilateral trans-radial, a right trans-tibial amputation and left midfoot amputation requiring chimeric partial scapula and latissimus dorsi muscle flaps, short perforator-based skin flaps and split skin grafts (Figures-1, Figure-2). The patient was otherwise previously fit and well, married with children and was a roofer by trade.

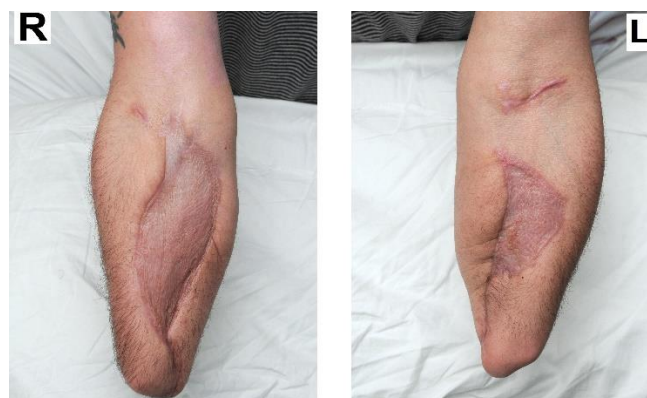

Figure-1. Bilateral transradial amputations

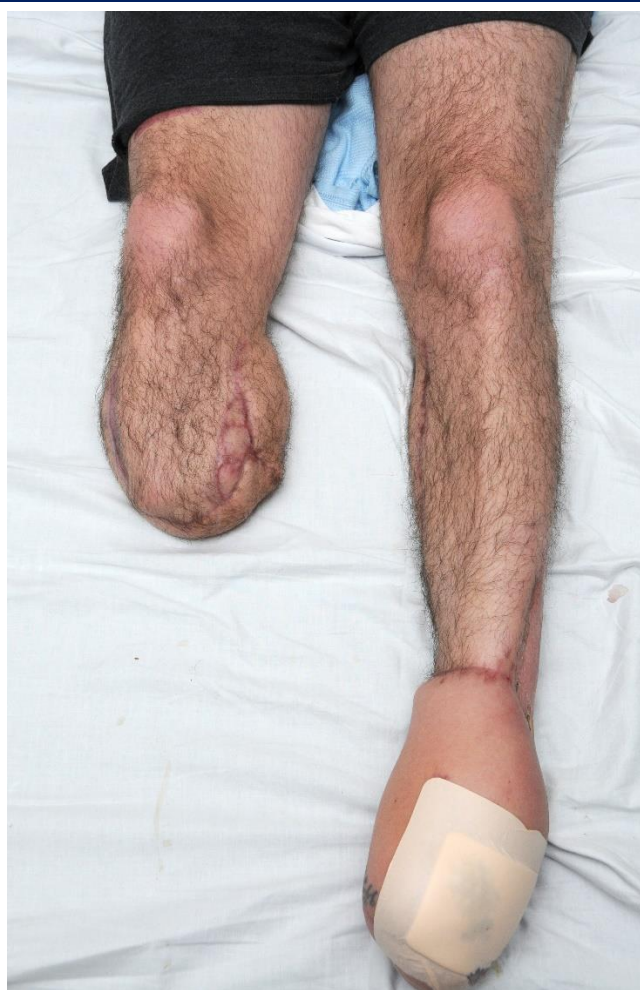

Figure-2. Right transtibial amputation and left midfoot amputation with infected wound (dressed)

On presentation to the Oxford Centre for Enablement, pain assessments using the numeric pain scale indicated that limb pain would be a significant barrier to optimal rehabilitation.

Sensory examination of the limbs indicated a combination of hyperalgesia and allodynia to light touch. The patient was also experiencing phantom limb pain. Examination of the patient's left mid-foot stump indicated non-resolving wound infections that required further debridement, antibiotic therapy and eventual left transtibial amputation two weeks

later which further contributed towards his pain.

A step- wise approach to pain management was followed in accordance with the World Health Organisation analgesic ladder starting with regular paracetamol and codeine, escalating to as required morphine. This failed to control his pain, so codeine was switched to tramadol. Amitriptyline, pregabalin and gabapentin were incrementally introduced.

Interestingly a combination of neuropathic agents was more effective than dose increasing one neuropathic agent alone. [Table-1](#) outlines the patient's final analgesic regimen. Wound pain secondary to infection managed initially with antibiotics and pain associated with localised swelling post wound healing was soothed with hydrocortisone ointment.

The patient was rehabilitated and underwent application of bilateral below-elbow prosthetic limbs with carbon fibre and metal hooks, static wrist units and below elbow appendages (Steppers) ([Figure-3](#)) with a detachable silicone covered cosmetic hands. For his lower limbs, bilateral lower leg prosthetic limbs with applied suspension sleeves, alpha gel liners, laminar pockets and Areis solution foot (Ortho Europe).

After a three month rehabilitation inpatient stay, he was subsequently discharged with pain controlled. At subsequent outpatient follow ups, the patient did not complain of any additional pains, including stump pain, phantom pain or neuroma-type pain.

Discussion

A rigorous search strategy was designed to interrogate the MEDLINE, EMBASE, CINAHL, PsycINFO databases to explore the evidence of pain management in electrocution injuries in the literature.

This strategy searched exact terms and derivatives of terms such as: pain, electrocution, electric injuries, management, analgesia, electric burns.

Table-1. Patient's final analgesic regime

Analgesic	Dose	Frequency	Indication
Paracetamol	1g	Four times per day	pain
Tramadol	100mg	Four times per day	pain
Amitriptyline	50mg	Once at night	pain
Pregabalin	200mg	Three times per day	pain
Hydrocortisone 1% ointment	One topical application	Once a day	pain / wound healing
Gabapentin	300mg	Once a day	pain

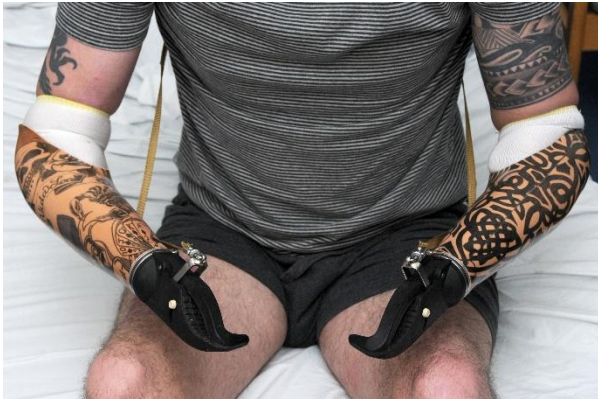

Figure-3. Bilateral below-elbow prosthetic limbs

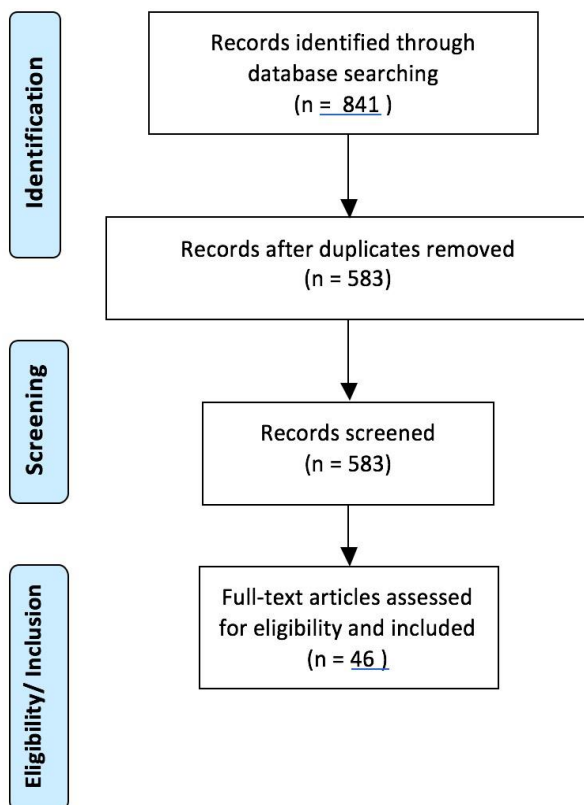


Figure-4. Literature search strategy

Eight hundred and forty-one studies were identified and after removal of duplicates and screening, 46 studies were considered (Figure-4). Studies were excluded if they were in non- English text and included if they investigated pain management of any sort in those with electrical injuries resulting in significant injury (fractures, amputations, burns) irrespective of the size or characteristics of the population considered. No randomised controlled trials, systematic reviews or meta-analyses dealing with the management of pain in severe electrocution injuries could be identified from the literature. Case reports and case series constituted the

final papers considered generally describing pain management using the following three approaches:

- **Orthopaedic/ Plastic intervention:** fixation of spinal compression fractures, shoulder fracture/ dislocation, scapular fractures, grafting of burns as a means of addressing the root cause of the pain.²⁻⁶
- **Medication:** Gabapentin and pregabalin has effectively been used in a patient with peripheral neuropathy following electrocution injury.^{7,8}

Interestingly, there is increasing evidence about the combined role of gabapentin and pregabalin in pain management which has been reported give a synergistic analgesic effect without clinically significant pharmacokinetic interactions. In addition, this combined regimen can reduce the dose the individual neuropathic analgesic and its side effects, and to enhance therapeutic response compared to a single agent.⁹ These previously reported findings were also seen in our case.

- **Nerve blocks:** Bilateral ultrasound guided supraclavicular blocks, cervical epidurals and stellate ganglion blocks have also been reportedly used to good effect for pain control in upper limb electrocution injuries.^{10,11}

- **Virtual Reality:** Oculus Rift Virtual Reality has been used in an 11-year-old child with electrical injuries effectively.¹²

No consensus could be found in the literature that exists as to the optimum management approach of pain in such patients. It is likely a flexible and multi-modal approach is required in cases of this sort. From our experience we suggest that a multi- modal analgesic approach is likely to be needed in patients with peripheral neuropathies secondary to electrocution injuries. Level 1 and 2 research into pain management in electrocution injuries is required.

Conclusion

Pain management in a patient with limb amputations secondary to severe electrical injuries can be expected to be challenging. No Level 1 evidence could be identified on this topic, most likely owing to the low incidence and therefore small patient numbers for data analysis. A multi-modal analgesic approach involving neuropathic medication is most likely required.

Acknowledgments

None.

Authors' Contribution

All authors pass the four criteria for authorship contribution based on the International Committee of Medical Journal Editors (ICMJE) recommendations.

Conflict of Interests

The authors declared no potential conflict of interests with respect to the research, authorship, and/or publication of this article.

Funding/Support

None.

References

1. Campbell R and Dini DA. Occupational Injuries from Electrical Shock and Arc Flash Events National Fire Protection Association: The Fire Protection Research Foundation; 2015.
2. Layton TR, McMurtry JM, McClain EJ, Kraus DR, Reimer BL. Multiple Spine Fractures from Electric Injury. *Journal of Burn Care & Research*. 1984;5(5):373-5.
3. Ketenci IE, Duymus TM, Ulusoy A, Yanik HS, Mutlu S, Durakbasa MO. Bilateral posterior shoulder dislocation after electrical shock: A case report. *Ann Med Surg (Lond)*. 2015; 4(4): 417–421.
4. Sibley PA, Godwin KA. Electrothermal ring burn from a car battery. *Orthopedics*. 2013;36(8):e1096-8.
5. Bachhal V, Goni V, Taneja A, Shashidhar BK, Bali K. Bilateral four-part anterior fracture dislocation of the shoulder--a case report and review of literature. *Bulletin of the NYU Hospital for Joint Diseases*. 2012; 70(4):268-72.
6. Huang WC, Chiu YH, How CK, Chen JD, Lam C. Posterior comminuted scapular fracture induced by a low-voltage electric shock. *The American Journal of Emergency Medicine*. 2010;28(9): 1060.e3-4.
7. Kara M, Yalcin S, Malas FU, Tiftik T, Ozcakar L. Ultrasound imaging for the upper limb nerves in CRPS: a patient with electrical injury. *Pain Physician*. 2014;17(4):E556-7.
8. Jarrell J, Spanswick C. Diagnostic use of infrared thermography in a patient with chronic pain following electrocution: a case report. *J Med Case Reports*. 2009;3:8992.
9. Senderovich H and Jeyapragasan G. Is there a role for combined use of gabapentin and pregabalin in pain control? Too good to be true? *Curr Med Res Opin*. 2018;34(4):677-682.
10. Gelpi B, Telang PR, Samuelson CG, Hamilton CS, Billiodeaux S. Bilateral ultrasound guided supraclavicular block in a patient with severe electrocution injuries of the upper extremities. *The Journal of the Louisiana State Medical Society : official organ of the Louisiana State Medical Society*. 2014;166(2):60-2.
11. Kim C-T, Bryant P. Complex Regional Pain Syndrome (Type I) After Electrical Injury: A Case Report of Treatment with Continuous Epidural Block. *Archives of Physical Medicine and Rehabilitation*. 2001;82(7):993-5.
12. Hoffman HG, Meyer WJ, Ramirez M, Roberts L, Seibel EJ, Atzori B, et al. Feasibility of Articulated Arm Mounted Oculus Rift Virtual Reality Goggles for Adjunctive Pain Control During Occupational Therapy in Pediatric Burn Patients. *Cyberpsychol Behav Soc Netw*. 2014;17(6):397-401.