



Isolated Displaced Capitate Fracture: A Case Report

Mohammad Zarei,¹ Arvin Najafi,^{1,*} Pejman Mansouri,¹ and Mahmoud Farzan¹

¹Joint Reconstruction Research Center, Tehran University of Medical Sciences, Tehran, Iran

*Corresponding author: Arvin Najafi, Joint Reconstruction Research Center, Imam Khomeini hospital, Bagherkhan st, Tehran, Iran. Tel: +98-9128576268, Fax: +98-2161192767, E-mail: parsmedicine@gmail.com

Received 2016 October 15; Revised 2017 February 15; Accepted 2017 April 24.

Abstract

Introduction: Isolated fractures of the capitate account for only 0.3% of carpal bones fractures.

Case Presentation: We report a motorbike rider, aged 27 years, who was involved in a motorcycle accident. He complained of right wrist pain, and wrist motion was considerably impaired. In the right wrist radiograph and CT scan, we diagnosed an isolated displaced capitate fracture. Open reduction was done under regional anaesthesia. After confirming the guide-wire's position and reduction of the fracture by imaging, we applied a headless compression screw (HCS, Synthes, Paoli, USA). After 24 months, the patient regained pain-free activity level with 90% of grip strength (in comparison with the contralateral wrist), with extension, flexion, radial deviation, ulnar deviation, supination, and pronation of 75°, 75°, 15°, 30°, 80°, and 80°, respectively.

Conclusions: This study suggested that an early diagnosis and open reduction of the displaced fragment in the treatment of such difficult fractures can lead to a successful outcome.

Keywords: Capitate Bone, Fracture, Wrist Injuries

1. Introduction

Capitate fracture is considered an uncommon injury to the carpal bones that comprises around 1.3% of all fractures of carpal bones (1). Most of these fractures are concomitant with other carpal lesions, predominantly the fracture of scaphoid. Isolated fractures of the capitate are accounted for only 0.3% of carpal bone fractures (2). Harrigan (3) first reported a case with such fracture in 1908. Dislocation of isolated fracture of capitate is very rare (2). The authors report a case of isolated displaced capitate fracture, which was managed well by open reduction and headless screw fixation. The healing of the bone occurs completely if an early diagnosis is made, while delayed diagnosis may lead to defective union by devascularisation (4, 5).

2. Case Presentation

A 27-year-old motorbike rider, involved in a motorcycle accident, was admitted with a skeletal injury of his right lower extremity. The fracture of tibial shaft was diagnosed and accordingly, the patient underwent open reduction and internal fixation. The day after surgery, he complained of right wrist pain. Wrist motion was considerably impaired. In the right wrist radiographs and CT scans, we

found isolated displaced capitate fracture (Figures 1-3). After open reduction, a dorsal approach was employed between the third and the fourth extensor compartments under regional anaesthesia. At the surgical site, there was no tear of ligaments. After confirming the guide-wire's position and reduction of the fracture by imaging, we applied a headless compression screw (HCS, Synthes, Paoli, USA) (Figures 4 and 5). The patient was immobilized in a short arm cast for 8 weeks. After confirming the union by wrist radiograph, the cast was removed (Figures 6 and 7). At this time, the active and passive range of motion was begun, followed by a wrist range of motion and grip strengthening exercises. After 24 months, the patient regained pain-free activity level with 90% of grip strength (in comparison with the contralateral wrist), with the extension, flexion, radial deviation, ulnar deviation, supination, and pronation of 75°, 75°, 15°, 30°, 80°, and 80°, respectively.

3. Discussion

Reports of capitate fractures commonly include Fenton's syndrome (6, 7) (concomitant fracture of both scaphoid and capitate), but only 0.3% of the fractures of the wrist are the isolated fracture of the capitate (1, 8). The isolated fracture of the capitate is uncommon because of its anatomic support; it is placed between the third and

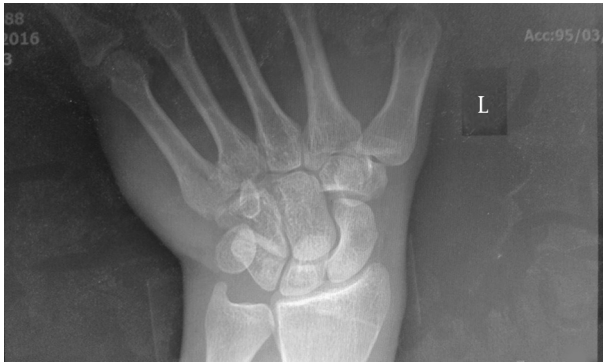

Figure 1. Preoperative Wrist Radiography in Scaphoid View

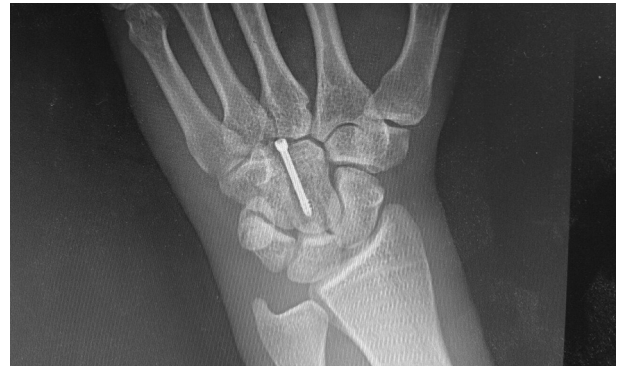

Figure 4. Postoperative Wrist Radiography in Anteroposterior (AP) View

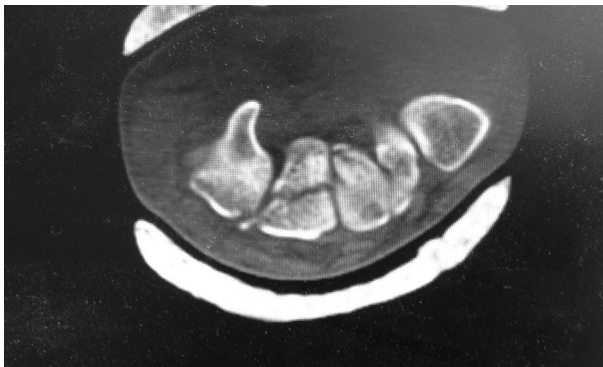

Figure 2. Preoperative Wrist CTs in Axial View

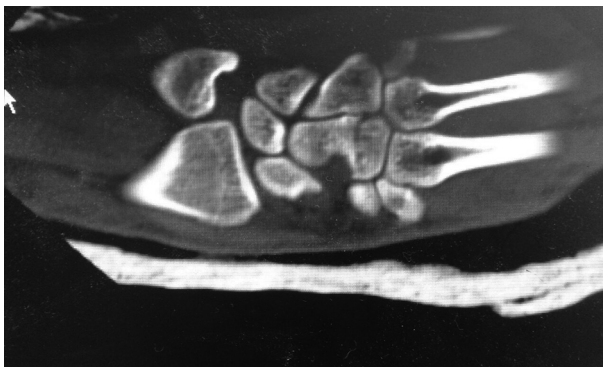


Figure 3. Preoperative Wrist CTs in Coronal View

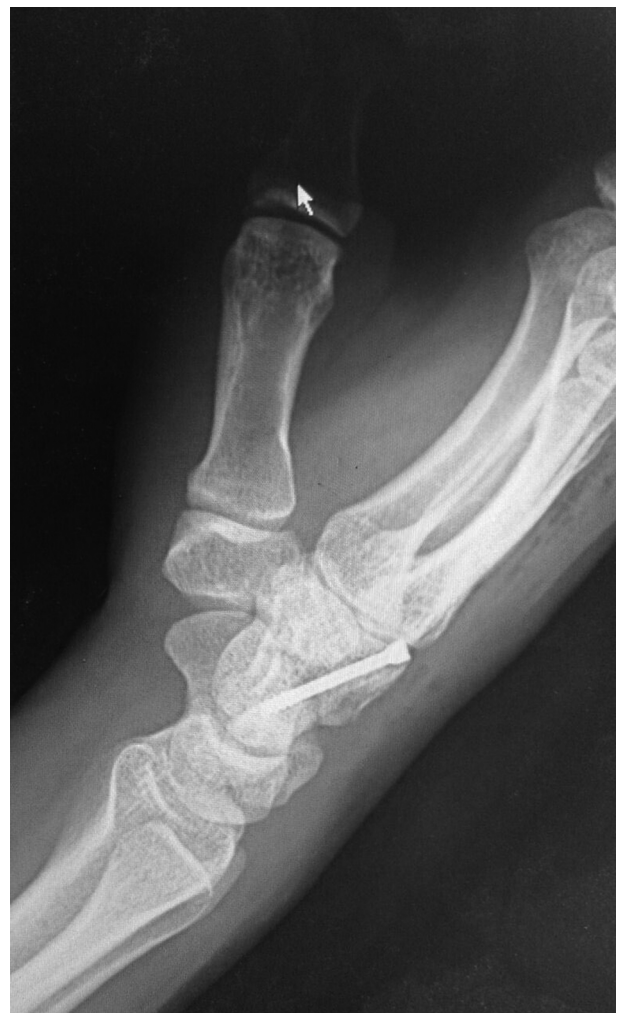

Figure 5. Postoperative Wrist Radiography in Lateral View

the fourth metacarpal bones the hamate, the lunate, the scaphoid, and the trapezoid and it is also protected from fractures because of its cuboidal morphology (6). Due to the intercarpal ligaments, most of its fractures remain dislocated (9). Isolated capitate fracture may be misdiagnosed because of the lack of clinical symptoms and its

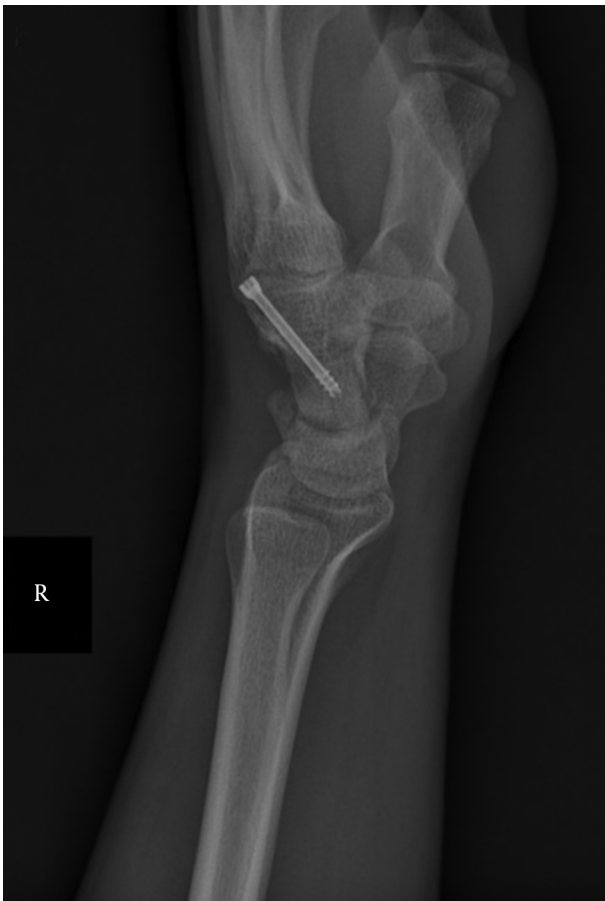

Figure 6. Wrist Radiography in Lateral View (After 3 Months of the Surgery)

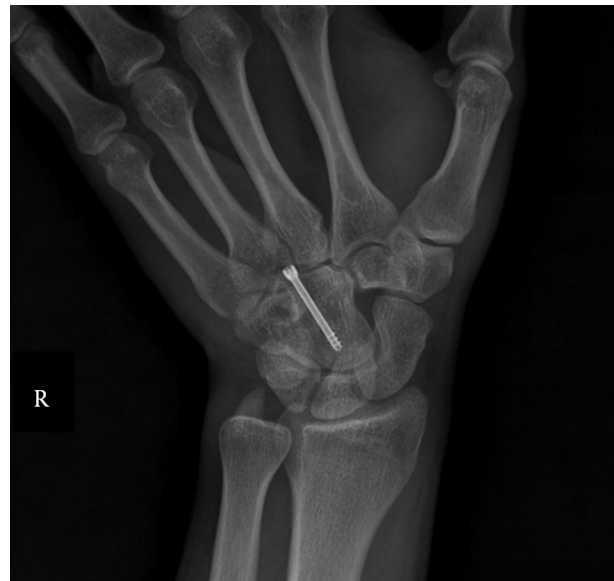

Figure 7. Wrist Radiography in Scaphoid View (After 3 Months of the Surgery)

ambiguous radiographs. Bone scan (10), CT scan (11), and MRI (9) have been recommended for these occult fractures. Johnson (12) reported that the lunate's posterior margin causes 'beheading' of the capitate, but with significant traumas with wrist hyperextension (1, 8). However, even minor repetitive traumas are believed to create bone damage by devascularization (4, 5, 13). Because of its primary vague symptoms, a delay in diagnosis frequently leads to non-union, avascular necrosis, and posttraumatic arthritis (5, 8, 13). In displaced fracture of the capitate, it is necessary to do anatomical reduction and internal fixation with headless compression screw (HCS) (2). The HCS is superior to the K-wire because of its compression to the site of the fracture, which permits an early range of motion. Immobilization is essential until the signs of fracture healing are evident. The most frequent complication is non-union: 19.6% to 56% in isolated capitate fractures (5, 14). Non-union is mostly the consequence of delayed diagnosis and paucity of primary sufficient treatment. A long-term possibility of midcarpal arthritis after isolated capitate fracture is controversial (14). In particular, because of the capitates' blood supply, we should consider vascular complications (4): the proximal fractures have greater possibility for necrosis (5, 13).

In our case, successful healing of the fracture was achieved and until now, there has been no sign of post-traumatic carpal arthritis and avascular necrosis. This study suggested that an early prompt diagnosis and open accurate reduction of the displaced fragment in the treat-

ment of such difficult fractures could lead to a successful outcome.

Footnotes

Funding/Support: There was no financial support.

Conflict of Interest: No conflict of interest.

References

- Rand JA, Linscheid RL, Dobyns JH. Capitate fractures: a long-term follow-up. *Clin Orthop Relat Res.* 1982;(165):209-16. [PubMed: 7075062].
- Amadio PC, Moran SL. *Fractures of the carpal bones.* In: Green DP, editor. *Green's operative hand surgery.* New York: Elsevier Churchill Livingstone; 2005.
- Harrigan AH. XVII. Fracture of the Os Magnum. *Ann Surg.* 1908;48(6):917-22. [PubMed: 17862282].
- Panagis JS, Gelberman RH, Taleisnik J, Baumgaertner M. The arterial anatomy of the human carpus. Part II: The intraosseous vascularity. *J Hand Surg Am.* 1983;8(4):375-82. [PubMed: 6886331].
- Yoshihara M, Sakai A, Toba N, Okimoto N, Shimokobe T, Nakamura T. Nonunion of the isolated capitate waist fracture. *J Orthopaed Sci.* 2002;7(5):578-80.
- Fenton RL. The naviculo-capitate fracture syndrome. *J Bone Joint Surg Am.* 1956;38-A(3):681-4. [PubMed: 13319423].
- Marcuzzi A, Ozben H, Russomando A, Petit A. Chronic transscaphoid, transcapitate perilunate fracture dislocation of the wrist: Fenton's syndrome. *Chir Main.* 2013;32(2):100-3. doi: 10.1016/j.main.2013.02.011. [PubMed: 23499268].
- Guiral J, Gracia A, Diaz-Otero JM. Isolated fracture of the capitate with a volar dislocated fragment. *Acta Orthop Belg.* 1993;59(4):406-8. [PubMed: 8116377].
- Calandruccio JH, Duncan SF. Isolated nondisplaced capitate waist fracture diagnosed by magnetic resonance imaging. *J Hand Surg Am.* 1999;24(4):856-9. [PubMed: 10447181].
- Hopkins SR, Ammann W. Isolated fractures of the capitate: use of nuclear medicine as an aid to diagnosis. *Int J Sports Med.* 1990;11(4):312-4. doi: 10.1055/s-2007-1024814. [PubMed: 2228362].
- Albertsen J, Mencke S, Christensen L, Teisen H, Hjarbak J. Isolated capitate fracture diagnosed by computed tomography. Case report. *Handchir Mikrochir Plast Chir.* 1999;31(2):79-81. doi: 10.1055/s-1999-13498. [PubMed: 10337550].
- Johnson RP. The acutely injured wrist and its residuals. *Clin Orthop Relat Res.* 1980;(149):33-44. [PubMed: 7408318].
- Vander Grend R, Dell PC, Glowczewskie F, Leslie B, Ruby LK. Intraosseous blood supply of the capitate and its correlation with aseptic necrosis. *J Hand Surg Am.* 1984;9(5):677-83. [PubMed: 6386955].
- Vigler M, Aviles A, Lee SK. Carpal fractures excluding the scaphoid. *Hand Clin.* 2006;22(4):501-16. abstract vii. doi: 10.1016/j.hcl.2006.07.007. [PubMed: 17097470].