

Denosumab and Atypical Femoral Fractures: A Scoping Literature Review

Ammar Ismail,¹ Amira Hassan Bekhet,² Abdelrahman Ibrahim Abushouk,^{3,4,*} Sahar Mirbaha,⁵ and Alireza Baratloo⁶

¹Faculty of Medicine, Al-Azhar University, Cairo, Egypt

²Faculty of Physical Therapy, Cairo University, Cairo, Egypt

³Faculty of Medicine, Ain Shams University, Cairo, Egypt

⁴NovaMed Medical Research Association, Cairo, Egypt

⁵Department of Emergency Medicine, Imam Hosein Hospital, Shahid Beheshti University of Medical Sciences, Tehran, Iran

⁶Department of Emergency Medicine, Sina Hospital, Tehran University of Medical Sciences, Tehran, Iran

* Corresponding author: Abdelrahman Ibrahim Abushouk, Ain Shams University, Postal code 11566, Cairo, Egypt. Tel: +20-1014295780, E-mail: abdelrahman.abushouk@med.asu.edu.eg

Received 2016 October 07; Accepted 2017 February 15.

Abstract

Background: Atypical femoral fracture (AFF) is a tensile fracture with unique radiographic and clinical features that differ from ordinary osteoporotic femoral fractures. Denosumab is a novel agent that inhibits osteoclastic activity, reducing bone resorption. Within the past few years, several case reports indicated that patients on denosumab prescription are at risk of AFF. The purpose of this review was to discuss the current evidence regarding this association and draw recommendations for clinicians about the use of denosumab in osteoporotic patients, until such evidence is established in future studies.

Methods: A computer search of Medline (through PubMed and OVID search) engines was conducted using the following keywords: "Denosumab" and "atypical femoral fractures". Furthermore, we reviewed the reference list of included studies for further citations.

Results: We identified 9 case reports, 5 clinical trials, and 1 prospective observational study that have reported data regarding the incidence of AFF in patients on denosumab prescription.

Conclusions: Denosumab is an effective treatment for osteoporosis; however, there is a growing number of reports regarding its association with AFF. Causality needs verification in future observational and interventional studies; meanwhile, screening for AFF in patients receiving denosumab and reevaluating the optimal antiresorptive therapy in osteoporotic patients is recommended.

Keywords: Atypical Femoral Fractures, Denosumab, Osteoporosis

1. Background

Atypical femoral fracture (AFF) is a tensile fracture characterized by unique radiographic and clinical features that differentiate it from ordinary osteoporotic femoral fractures (1). The term "atypical" was assigned in 1978 by Barcsa et al. (2) to describe fatigue fractures. After that, several case reports, case series, and registry-based studies reported the occurrence of AFF (3, 4). The American society for bones and mineral research (ASBMR) held a meeting to solve questions related to this problem (5) by reviewing the literature on AFF from 1990 to 2010 to set a case definition for AFF with specific criteria that differentiate it from other types of femoral fractures. These criteria act as a guide for subsequent studies to report any finding with the same definition criteria, as illustrated in Table 1. All major criteria are required to fulfil the case definition for AFF, while none of the minor criteria are required, but sometimes they have been associated with AFF (1).

The proximal one-third of the femoral shaft is the most common site for AFF. These fractures represent 17% to 29%

of subtrochanteric and diaphyseal fractures (6). They also represent 0.4% of all fractures, occurring in patients on Bisphosphonates (BPs) therapy (6, 7).

Denosumab is an FDA approved antiresorptive agent, available for osteoporosis treatment and fracture prevention (8). It inhibits bone resorption and increases cortical and trabecular bone mass and strength. It acts through blocking the effect of the receptor activator of nuclear factor KB ligand (RANKL), preventing its binding to receptors and decreasing bone resorption by osteoclasts. Denosumab is administered subcutaneously every 6 months at a dosage of 60 mg to treat osteoporosis (9, 10). In studies comparing denosumab and BPs, denosumab was proven to have a more potent and a long lasting effect than BPs, particularly in postmenopausal osteoporotic females (11, 12).

Recently, several case reports have been published on the occurrence of AFFs in denosumab treated patients (13-15). The exact incidence of AFF is still unknown for the general population without osteoporosis who are not ex-

Table 1. ASBMR Major and Minor Criteria for Diagnosis of AFF

Criteria	Description
Major	
1	The fracture is associated with no or minimal trauma, as in a fall from a standing height or less.
2	The fracture is noncomminuted or minimally comminuted.
3	Complete fractures that extend through both cortices and may be associated with a medial spike, whereas incomplete fractures involve only the lateral cortex.
4	The fracture line originates at the lateral cortex to be transverse in its orientation, or it may be oblique as it progresses medially across the femur.
5	Located anywhere along the femoral diaphysis from the area just below the lesser trochanter, to the supracondylar flare of the distal femoral metaphysis.
Minor	
1	Generalized increase in cortical thickness of the femoral diaphysis.
2	Unilateral or bilateral prodromal symptoms, such as dull or aching pain in the groin or thigh.
3	Delayed healing.
4	Usage of pharmaceutical agents such as BPs, glucocorticoids (GCs), proton pump inhibitors.
5	Presence of comorbid conditions such as vitamin D deficiency, Rheumatoid Arthritis, hypophosphatasia.

posed to antiresorptive drugs, and for osteoporotic patients exposed to antiresorptive drugs. These missing data may lead to misinterpreting the association between AFF and its causality (1). Are these fractures related to antiresorptive drugs such as denosumab or are they generally attributed to baseline conditions as osteoporosis? The present review aimed at discussing the current evidence on the association between denosumab and the incidence of AFF and providing recommendations for clinicians to use denosumab in osteoporotic patients until such evidence is established in future studies.

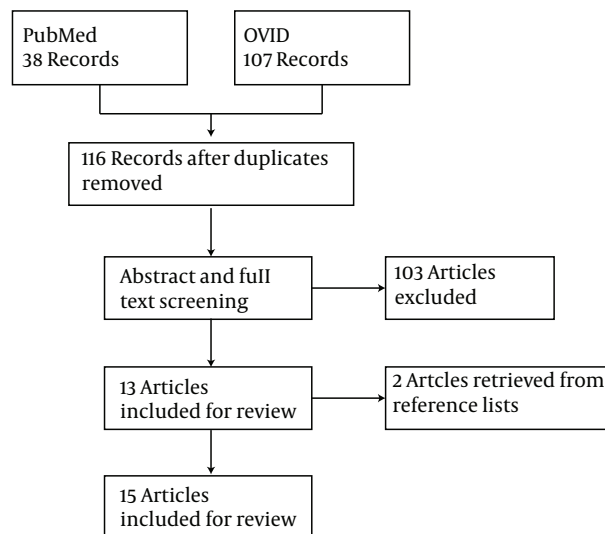
2. Methods

We searched Medline database through PubMed and OVID search engines during July 2016 for English original articles reporting on the occurrence of AFF in denosumab treated patients. We used the following keywords: “Denosumab” and “Atypical femoral fracture”.

Two authors (Ismail A. and Bekhet A.H.) independently reviewed the titles and abstracts of search results; and if the abstract was not conclusive, the full text was obtained to make a cutoff decision. Disagreements were resolved by a third reviewer. We also conducted a manual search for articles cited in included studies.

3. Results

Our search of PubMed and OVID databases, using the key words “(atypical femoral fractures) AND (denosumab)”, retrieved 116 unique records. Fifteen articles (9 case reports, 5 clinical trials, and 1 observational study) met the inclusion criteria and were included in this scoping review (Figure 1).

**Figure 1.** The Search Strategy for Primary Reports of AFF in Denosumab Treated Patients

3.1. Case Reports

Nine case reports were published about the occurrence of AFF in patients receiving denosumab from 2013 to 2016. Table 2 summarizes the main characteristics of these reports and the criteria of their patients.

3.2. Observational Studies

One single-arm prospective observational study by Silverman et al. 2015, concluded that no cases of AFF were reported over 24 months in 935 postmenopausal females who were enrolled within 4 weeks after the first subcutaneous injection of denosumab (14).

3.3. Clinical Trials

The FREEDOM trial, an open label study of 4500 postmenopausal females, had a 7-year extended program to evaluate the effect of denosumab subcutaneous injection every 6 months on bone mineral density of the enrolled participants. The results of the study revealed that AFF is a rare occurrence with denosumab prolonged use (1 to 10:

Table 2. The Findings of the Published Case Reports About the Occurrence of AFF in Denosumab Treated Patients

Study ID	Age, y	Sex (M/F)	Denosumab Dose, n	Concurrent Illness	Other Antiresorptive Drugs	Fracture	Treatment
Villiers, Clark, Jeswani, Webster, and Hepburn, 2013	78	F	3	Rheumatoid arthritis	Alendronate and strontium	Unilateral non-comminuted fracture with medial spike	Anterograde interlocked femoral nailing with reaming
Paparodis, Buehring, Pelley, and Binkley, 2013	81	F	1	Chronic kidney disease and Hyperparathyroidism	Estrogen therapy	Unilateral transverse subtrochanteric	treated conservatively with non-weight bearing
Thompson, Armstrong, and Heyburn, 2014	59	F	1	Rheumatoid arthritis	Alendronate	Bilateral, with a three months interval	Anterograde interlocked femoral nailing with reaming
Drampalos, Skarpas, Barbounakis, and Michos, 2014	73	F	1 dose before 1st fracture then 2 doses before 2nd fracture	-	Alendronate	Bilateral transverse femoral shaft fractures, with a one year interval	Anterograde interlocked femoral nailing with reaming
Schilcher and Aspenberg, 2014	83	F	3 doses before 2nd fracture	-	Alendronate and zoledronate	Bilateral (1st complete and the 2nd incomplete)	Anterograde interlocked femoral nailing with reaming
Khow and Yong, 2015	72	F	3	Chronic obstructive pulmonary disease	Alendronate and strontium	Unilateral subtrochanteric fracture	Anterograde interlocked femoral nailing with reaming
Ramchand, Chiang, Zebaze, and Seeman, 2016	82	F	1	Diabetes mellitus	Prior bisphosphonates therapy	bilateral recurrent incomplete	Bilateral internal fixation
Selga, Nunez, Minguell, Lalanza, and Garrido, 2016	62	F	5	-	Alendronate, risedronate, and ibandronate	Bilateral Simultaneous	Anterograde interlocked femoral nailing with reaming
Ohnaru, 2016	62	F	15 (120 mg every 4 weeks)	Breast cancer	Zoledronate	Unilateral subtrochanteric fracture	Anterograde interlocked femoral nailing with reaming

10,000 patients on denosumab 60 mg for 30 months) (16, 17).

Other 4 clinical trials (an open label trial by Recknor et al. 2013) reported no cases of AFF ($n = 0$) over a 6-month period (18). The other three double blinded trials (Orwoll et al. 2012; McClung et al. 2013; and Freemantle et al. 2012) reported no cases of AFF in postmenopausal females receiving denosumab ($n = 0$) over 1, 2, and 4 years, respectively (19-21).

4. Discussion

Due to its antiresorptive activity, a growing number of case reports suggests an association between denosumab and AFFs, despite its rarity. Some common features exist among the discussed case reports in this review. In all of them, the patients were elderly females. Five cases of bilateral AFF have been reported (One case of simultaneous

bilateral fractures (22) and 4 cases in which the 2 fractures occurred separately (13, 23-25)).

The current evidence is primarily limited to case reports, which are highly confounded by the former use of BPs and glucocorticoids, which have an established relationship with AFF (in all 9 reports except 1 case by Paparodis et al. 2013 (26)). Uncertainty is further extended by the notion that 4 of these cases occurred after receiving only 1 dose of denosumab (13, 23, 24, 26). This finding favors the theory that AFF results from fresh microcracks, for which remodeling is impaired, not the disturbance of bone tissue properties.

Data from the published FREEDOM trial revealed that the benefits of denosumab in osteoporosis outbalance the risk of the rare occurrence of AFF. It decreased the risk of vertebral fractures by 68%, nonvertebral fractures by 20%, and hip fractures by 40% (16, 17). Intriguingly, no cases of AFF have been reported in oncology studies, in which

denosumab is used at a higher dosage than that of osteoporosis treatment trials. However, only 1 case report by Ohnaru et al. (27) reported a case of AFF in a breast cancer patient receiving denosumab for bone metastasis. An advisory has warned about severe hypocalcemia, reported at such high doses (28). Further epidemiological studies with larger sample size and radiographic adjudication are required to verify the association between denosumab and AFF.

The exact pathophysiology of AFF in patients receiving antiresorptive drugs including denosumab has not yet been established. A major hypothesis is that antiresorptive drugs inhibit bone turnover leading to accumulation of microdamage and increasing the risk of AFF (1). Also, such inhibition leads to accumulation of advanced glycation end-products in collagen-B fibers, leading to increased bone brittleness (29). Moreover, the antiangiogenic properties of these drugs do not allow the repair of such accumulating damage (30). For denosumab, it specifically binds to RANKL on osteoclast precursors, suppressing the formation of new osteoclasts and inhibiting the activity of the existing cells. Therefore, bone matrix is not replaced and undergoes secondary mineralization (a form of premature bone aging), reducing its ability to deform during loading to absorb energy. The small change of normal bone mineralization density distribution (BMDD) impairs the ability of bone to resist cracks, which is directly proportional to the bone stiffness ratio (13).

It would be valuable to develop a screening tool to identify patients at risk of AFF and count them ineligible for antiresorptive drug therapy. The correlation between tissue mineralization density and the level of circulating cross-linked collagen with the occurrence of AFF should be established because these biomarkers may serve as a signal to identify patients at risk of similar fractures (13). Because osteoporosis is involved in the pathogenesis of these fractures, appropriate lifestyle interventions such as calcium/vitamin D rich diet or supplements and measures to prevent falling can improve bone density (28).

Despite lack of evidence, it is recommended that once these fractures are suspected, a plain x-radiography of both femurs be obtained. Confirmation through MRI should follow if doubt persists (31). In a recent scoping review by Toro et al. they outlined an approach to manage AFF, based on clinical experience and diverse data from the literature. They suggested that patients with complete fractures should undergo surgical repair using plates or intramedullary nails, while those with incomplete fractures can be managed conservatively through non-weight bearing and medical supplements, then follow up by regular x-ray imaging for 3 months. If no healing occurs or the fracture line progressed, operative management should be

considered (32).

It is plausible that once these fractures occur, antiresorptive medications should be stopped (33). Other options to manage osteoporosis include monoclonal antisclerostin antibodies, which enhance bone formation (34). Some authors suggested shifting to a weaker antiresorptive agent such as raloxifene, which increases bone toughness through increasing its water content without affecting tissue mineral composition (13). Chiang et al. reported that teriparatide prescription improves the healing of AFF; however, this finding needs to be further verified (35). Further randomized clinical trials are needed to verify the safety and efficacy of these strategies in detection and treatment of AFF.

4.1. Conclusions

Denosumab is an effective antiresorptive agent; however, a growing number of reports indicates its possible association with AFF. Causality needs verification in future observational and interventional studies; meanwhile, screening for AFF in patients receiving denosumab and reevaluating the optimal antiresorptive therapy in osteoporotic patients is recommended.

Footnotes

Competing Interests: None of the authors has any competing interest to declare.

Funding/Support: None.

References

1. Shane E, Burr D, Abrahamsen B, Adler RA, Brown TD, Cheung AM, et al. Atypical subtrochanteric and diaphyseal femoral fractures: second report of a task force of the American Society for Bone and Mineral Research. *J Bone Miner Res*. 2014;29(1):1-23. doi: [10.1002/jbmr.1998](https://doi.org/10.1002/jbmr.1998). [PubMed: [23712442](https://pubmed.ncbi.nlm.nih.gov/23712442/)].
2. Barcsa C, Endes J, Szapannos L. [Atypical fatigue fractures]. *Beitr Orthop Traumatol*. 1978;25(10):578-82. [PubMed: [728040](https://pubmed.ncbi.nlm.nih.gov/728040/)].
3. Kwek EB, Goh SK, Koh JS, Png MA, Howe TS. An emerging pattern of subtrochanteric stress fractures: a long-term complication of alendronate therapy?. *Injury*. 2008;39(2):224-31. doi: [10.1016/j.injury.2007.08.036](https://doi.org/10.1016/j.injury.2007.08.036). [PubMed: [18222447](https://pubmed.ncbi.nlm.nih.gov/18222447/)].
4. Nieves JW, Bilezikian JP, Lane JM, Einhorn TA, Wang Y, Steinbuch M, et al. Fragility fractures of the hip and femur: incidence and patient characteristics. *Osteoporos Int*. 2010;21(3):399-408. doi: [10.1007/s00198-009-0962-6](https://doi.org/10.1007/s00198-009-0962-6). [PubMed: [19484169](https://pubmed.ncbi.nlm.nih.gov/19484169/)].
5. Desai PA, Vyas PA, Lane JM. Atypical femoral fractures: a review of the literature. *Curr Osteoporos Rep*. 2013;11(3):179-87. doi: [10.1007/s11914-013-0167-y](https://doi.org/10.1007/s11914-013-0167-y). [PubMed: [24048722](https://pubmed.ncbi.nlm.nih.gov/24048722/)].
6. Giusti A, Hamdy NA, Dekkers OM, Ramautar SR, Dijkstra S, Papapoulos SE. Atypical fractures and bisphosphonate therapy: a cohort study of patients with femoral fracture with radiographic adjudication of fracture site and features. *Bone*. 2011;48(5):966-71. doi: [10.1016/j.bone.2010.12.033](https://doi.org/10.1016/j.bone.2010.12.033). [PubMed: [21195812](https://pubmed.ncbi.nlm.nih.gov/21195812/)].

7. Martinet O, Cordey J, Harder Y, Maier A, Buhler M, Barraud GE. The epidemiology of fractures of the distal femur. *Injury*. 2000;**31** Suppl 3:C62-3. [PubMed: [1052383](#)].
8. Cummings SR, San Martin J, McClung MR, Siris ES, Eastell R, Reid IR, et al. Denosumab for prevention of fractures in postmenopausal women with osteoporosis. *N Engl J Med*. 2009;**361**(8):756-65. doi: [10.1056/NEJMoa0809493](#). [PubMed: [19671655](#)].
9. Dempster DW, Laming CL, Kostenuik PJ, Grauer A. Role of RANK ligand and denosumab, a targeted RANK ligand inhibitor, in bone health and osteoporosis: a review of preclinical and clinical data. *Clin Ther*. 2012;**34**(3):521-36. doi: [10.1016/j.clinthera.2012.02.002](#). [PubMed: [22440513](#)].
10. Simon JA, Recknor C, Moffett AJ, Adachi JD, Franek E, Lewiecki EM, et al. Impact of denosumab on the peripheral skeleton of postmenopausal women with osteoporosis: bone density, mass, and strength of the radius, and wrist fracture. *Menopause*. 2013;**20**(2):130-7. doi: [10.1097/gme.0b013e318267f909](#). [PubMed: [23010883](#)].
11. Beaudoin C, Jean S, Bessette L, Ste-Marie LG, Moore L, Brown JP. Denosumab compared to other treatments to prevent or treat osteoporosis in individuals at risk of fracture: a systematic review and meta-analysis. *Osteoporos Int*. 2016;**27**(9):2835-44. doi: [10.1007/s00198-016-3607-6](#). [PubMed: [27120345](#)].
12. Lewiecki EM. Treatment of osteoporosis with denosumab. *Maturitas*. 2010;**66**(2):182-6. doi: [10.1016/j.maturitas.2010.02.008](#). [PubMed: [20236778](#)].
13. Ramchand SK, Chiang CY, Zebaze RM, Seeman E. Recurrence of bilateral atypical femoral fractures associated with the sequential use of teriparatide and denosumab: a case report. *Osteoporos Int*. 2016;**27**(2):821-5. doi: [10.1007/s00198-015-3354-0](#). [PubMed: [26458389](#)].
14. Silverman SL, Siris E, Kendler DL, Belazi D, Brown JP, Gold DT, et al. Persistence at 12 months with denosumab in postmenopausal women with osteoporosis: interim results from a prospective observational study. *Osteoporos Int*. 2015;**26**(1):361-72. doi: [10.1007/s00198-014-2871-6](#). [PubMed: [25236877](#)].
15. Aspenberg P. Denosumab and atypical femoral fractures. *Acta Orthop*. 2014;**85**(1):1. doi: [10.3109/17453674.2013.859423](#). [PubMed: [24171676](#)].
16. Papapoulos S, Lippuner K, Roux C, Lin CJ, Kendler DL, Lewiecki EM, et al. The effect of 8 or 5 years of denosumab treatment in postmenopausal women with osteoporosis: results from the FREEDOM Extension study. *Osteoporos Int*. 2015;**26**(12):2773-83. doi: [10.1007/s00198-015-3234-7](#). [PubMed: [26202488](#)].
17. Bone HG, Chapurlat R, Brandi ML, Brown JP, Czerwinski E, Krieg MA, et al. The effect of three or six years of denosumab exposure in women with postmenopausal osteoporosis: results from the FREEDOM extension. *J Clin Endocrinol Metab*. 2013;**98**(11):4483-92. doi: [10.1210/jc.2013-1597](#). [PubMed: [23979955](#)].
18. Recknor C, Czerwinski E, Bone HG, Bonnick SL, Binkley N, Palacios S, et al. Denosumab compared with ibandronate in postmenopausal women previously treated with bisphosphonate therapy: a randomized open-label trial. *Obstet Gynecol*. 2013;**121**(6):1291-9. doi: [10.1097/AOG.0b013e318291718c](#). [PubMed: [23812464](#)].
19. Orwoll E, Teglbaerg CS, Langdahl BL, Chapurlat R, Czerwinski E, Kendler DL, et al. A randomized, placebo-controlled study of the effects of denosumab for the treatment of men with low bone mineral density. *J Clin Endocrinol Metab*. 2012;**97**(9):3161-9. doi: [10.1210/jc.2012-1569](#). [PubMed: [22723310](#)].
20. McClung MR, Lewiecki EM, Geller ML, Bolognese MA, Peacock M, Weinstein RL, et al. Effect of denosumab on bone mineral density and biochemical markers of bone turnover: 8-year results of a phase 2 clinical trial. *Osteoporos Int*. 2013;**24**(1):227-35. doi: [10.1007/s00198-012-2052-4](#). [PubMed: [22776860](#)].
21. Freemantle N, Satram-Hoang S, Tang ET, Kaur P, Macarios D, Sidhanti S, et al. Final results of the DAPS (Denosumab Adherence Preference Satisfaction) study: a 24-month, randomized, crossover comparison with alendronate in postmenopausal women. *Osteoporos Int*. 2012;**23**(1):317-26. doi: [10.1007/s00198-011-1780-1](#). [PubMed: [21927922](#)].
22. Selga J, Nunez JH, Minguell J, Lalanza M, Garrido M. Simultaneous bilateral atypical femoral fracture in a patient receiving denosumab: case report and literature review. *Osteoporos Int*. 2016;**27**(2):827-32. doi: [10.1007/s00198-015-3355-z](#). [PubMed: [26501556](#)].
23. Thompson RN, Armstrong CL, Heyburn G. Bilateral atypical femoral fractures in a patient prescribed denosumab - a case report. *Bone*. 2014;**61**:44-7. doi: [10.1016/j.bone.2013.12.027](#). [PubMed: [24389366](#)].
24. Drampalos E, Skarpas G, Barbounakis N, Michos I. Atypical femoral fractures bilaterally in a patient receiving denosumab. *Acta Orthop*. 2014;**85**(1):3-5. doi: [10.3109/17453674.2013.854668](#). [PubMed: [24171686](#)].
25. Schilcher J, Aspenberg P. Atypical fracture of the femur in a patient using denosumab—a case report. *Acta Orthop*. 2014;**85**(1):6-7. doi: [10.3109/17453674.2014.885355](#). [PubMed: [24460109](#)].
26. Paparodis R, Buehring B, Pelley EM, Binkley N. A case of an unusual subtrochanteric fracture in a patient receiving denosumab. *Endocr Pract*. 2013;**19**(3):e64-8. doi: [10.4158/EP12367.CR](#). [PubMed: [23337161](#)].
27. Ohnaru K, Kawamoto T, Yamamoto Y, Tanaka K, Mitani S, Hasegawa T. Atypical Femoral Fracture in a Patient with Metastatic Breast Cancer During Denosumab Therapy. *J Clin Case Rep*. 2016;**201**.
28. Villiers J, Clark DW, Jeswani T, Webster S, Hepburn AL. An atraumatic femoral fracture in a patient with rheumatoid arthritis and osteoporosis treated with denosumab. *Case Rep Rheumatol*. 2013;**2013**:249872. doi: [10.1155/2013/249872](#). [PubMed: [24490096](#)].
29. Ettinger B, Burr DB, Ritchie RO. Proposed pathogenesis for atypical femoral fractures: lessons from materials research. *Bone*. 2013;**55**(2):495-500. doi: [10.1016/j.bone.2013.02.004](#). [PubMed: [23419776](#)].
30. Wood J, Bonjean K, Ruetz S, Bellahcene A, Devy L, Foidart JM, et al. Novel antiangiogenic effects of the bisphosphonate compound zoledronic acid. *J Pharmacol Exp Ther*. 2002;**302**(3):1055-61. doi: [10.1124/jpet.102.035295](#). [PubMed: [12183663](#)].
31. Neviaser AS, Lane JM, Lenart BA, Edobor-Osula F, Lorch DG. Low-energy femoral shaft fractures associated with alendronate use. *J Orthop Trauma*. 2008;**22**(5):346-50. doi: [10.1097/BOT.0b013e318172841c](#). [PubMed: [18448990](#)].
32. Toro G, Ojeda-Thies C, Calabro G, Toro G, Moretti A, Guerra GM, et al. Management of atypical femoral fracture: a scoping review and comprehensive algorithm. *BMC Musculoskelet Disord*. 2016;**17**:227. doi: [10.1186/s12891-016-1086-8](#). [PubMed: [27215972](#)].
33. Schilcher J, Michaelsson K, Aspenberg P. Bisphosphonate use and atypical fractures of the femoral shaft. *N Engl J Med*. 2011;**364**(18):1728-37. doi: [10.1056/NEJMoa1010650](#). [PubMed: [21542743](#)].
34. Li X, Ominsky MS, Warmington KS, Morony S, Gong J, Cao J, et al. Sclerostin antibody treatment increases bone formation, bone mass, and bone strength in a rat model of postmenopausal osteoporosis. *J Bone Miner Res*. 2009;**24**(4):578-88. doi: [10.1359/jbmr.081206](#). [PubMed: [19049336](#)].
35. Chiang CY, Zebaze RM, Ghasem-Zadeh A, Iuliano-Burns S, Hardidge A, Seeman E. Teriparatide improves bone quality and healing of atypical femoral fractures associated with bisphosphonate therapy. *Bone*. 2013;**52**(1):360-5. doi: [10.1016/j.bone.2012.10.006](#). [PubMed: [23072919](#)].