

Transradial Styloid Perilunate Dislocation: A Rare Case

Hassan Rahimi,¹ Ali Parsa,^{1,2,*} Alireza Hotkani,¹ Maryam Mirzaie,³ and Marjan Assadian¹

¹Orthopedic Research Center, Department of Orthopedic Surgery, Mashhad University of Medical Sciences, Mashhad, Iran

²Texas Scottish Rite Hospital, Dallas, USA

³Department of Community Medicine, Department of Orthopedic Surgery, Mashhad University of Medical Sciences, Mashhad, Iran

*Corresponding author: Ali Parsa, Orthopedic Research Center, Department of Orthopedic Surgery, Mashhad University of Medical Sciences, Mashhad, Iran. Tel: +98-5118022695, E-mail: ali.parsa@tsrh.org, Parsaa@mums.ac.ir

Received 2016 September 06; Revised 2017 February 26; Accepted 2017 March 11.

Abstract

Although perilunate fracture-dislocation usually extremely alters the inter-carpal relationships, it is frequently misinterpreted during initial evaluations. We report two 30-year-old males with a very rare transradial styloid perilunate fracture-dislocation treated by closed reduction and percutaneous K-wire fixation. They regained the range of motion (ROM) of their wrists and furthermore, the mid-term outcome turned out to be satisfactory.

Keywords: Styloid, Fracture, Perilunate, Transradial

1. Introduction

Wrist is a complex joint with various types of ligaments that support its integrity as well as the complex motions between radiocarpal and intercarpal structures (1). The integrity of bones and ligaments in this joint guarantee the stability and flexibility of the wrist. The scaphoid bone tends to flex under compressive load, and as a result, it exerts a similar torque to the lunate, which might turn the dorsal ward. On the other hand, triquetrum tends to extend under compressive loading; therefore, it might cause the lunate to move into extension. The lunate is in a state of dynamic balance between these 2 antagonists (2). When the dynamic balance is interrupted, the lunate tends to flex, causing a loss of ulnar support from the triquetrum. It is also likely to extend if there is a loss of radial stability (3). Consequently, when an outstretched hand is heavily loaded by radial deviation and dorsiflexion force, the scaphoid is compressed against the radial styloid. This condition might lead to radial styloid fracture, radiolunate and scapholunate ligament rupture. Eventually, the distal row, which is attached to the radial styloid, might dislocate dorsoradial (1, 3). Scapholunate intercarpal ligament is the most important stabilizer ligament (4). In cases of transradial styloid perilunate fracture-dislocation, this ligament is disrupted; thus, it is recommended to repair it by open reduction and/or another ligament repair method referred to as midcarpal arthrodesis (5). Transradial styloid perilunate fracture-dislocation is a very rare condition, which is supposed to be caused by axial loading and dorsiflexion force along with intercarpal supination; a mechanism that occurs upon an abrupt fall onto an outstretched, pronated hand. A few cases of such injury

are reported, which mostly accounted for trans-capitate and trans-triquetral perilunate fracture-dislocation (6, 7). Two rare cases of transradial styloid perilunate fracture-dislocation are presented here.

2. Case Presentation

2.1. Case 1

A 30-year-old male was admitted to the orthopedic department of Emam-Reza general hospital, Mashhad, Iran, for an outstretched hand injury caused in a motorcycle accident. Clinical examinations showed abnormal swelling and prominence in the dorsal aspect of the right wrist without any open wounds. The patient's right hand and digits were well-perfusing. The patient denied any paresthesia and had symmetric sensation of the hand and digits. Wrist radiographs disclosed radial styloid fracture, scaphoid and capitates displaced dorsally, radiolunate angle increased in lateral view and a distinct Terry Thomas sign (marked scapholunate gap in posteroanterior view) (Figures 1 and 2). The findings led to the diagnosis of a transradial styloid perilunate fracture-dislocation. During surgery, closed reduction was performed with percutaneous fixation under fluoroscopic control, and anatomic reduction was conducted as well. Two K-wires under C-arm guide were applied to fix the radiolunate. Two others were used for the radial styloid fixation, and the last one managed to transfix the scapholunate. Eventually, a perfect reduction was achieved in the postoperative radiograph (Figure 3). A long arm cast was applied and it was decided to keep the K-wires on the patient for the next 8 weeks. Within 20 months, full wrist range of motion (ROM) was regained (flexion: 30°; dorsiflexion: 35°) and the patient did

not complain of loss of grip or other difficulties in daily activities.

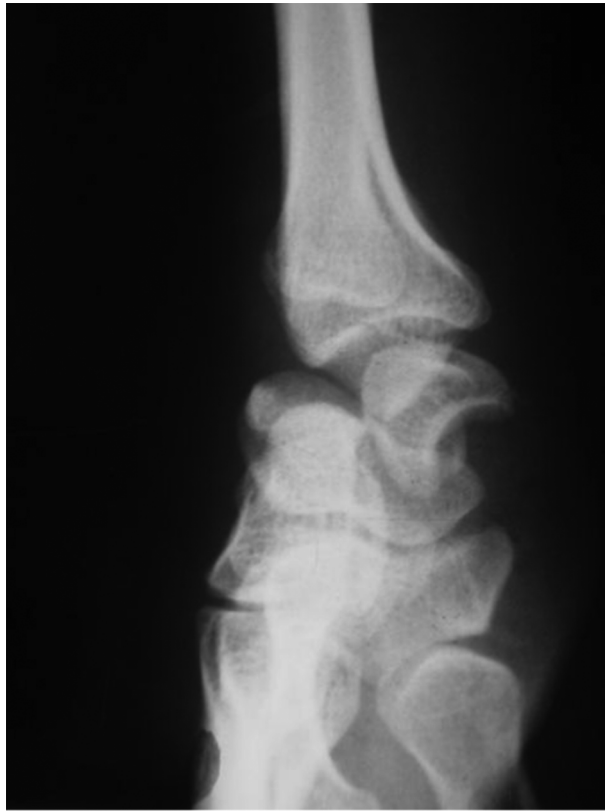

Figure 1. Wrist Radiographs

2.2. Case 2

A 30-year-old male with severe wrist pain, which was a result of a motorcycle accident, referred to Emam-Reza general hospital, Mashhad, Iran. On posteroanterior and lateral radiographs of the wrist, it was found out that the wrist had been dislocated as in a case of transradial styloid perilunate fracture-dislocation ([Figures 1 and 2](#)). During the operation, under fluoroscopic control, closed reduction was tried. The reduction was so perfect that it was decided to stabilize it with percutaneous multiple pin fixation. Afterwards, no distance was observed between the fractured dislocated parts. The procedure was finalized using a long arm cast. Postoperative radiographs are illustrated in [Figure 3](#). The cast was removed after 2 months. After 2 years of follow-up, the patient was symptom-free with a satisfactory ROM (flexion: 30°; dorsiflexion: 40°).

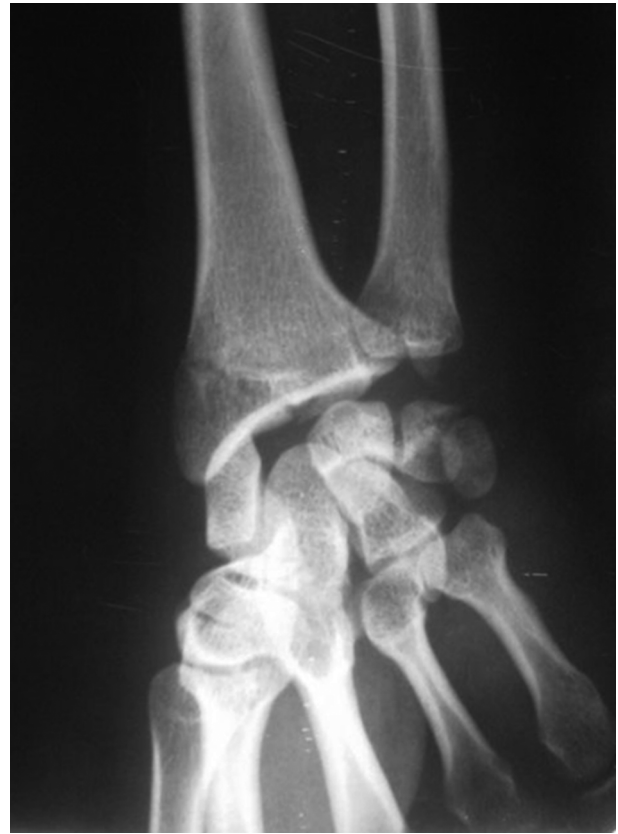

Figure 2. Transradial Styloid Perilunate Fracture-Dislocation

3. Discussion

Although perilunate fracture-dislocation usually extremely alters the intercarpal relationships, it is frequently misinterpreted during initial evaluations. Prompt identification is required to obtain an accurate diagnosis and treatment of such injuries. The mechanism of injury is often hyperextension ulnar deviation and intercarpal supination ([8](#)). They are categorized under a subgroup called greater arc perilunate dislocations. However, transradial styloid perilunate dislocation is a very rare type of injury. Majeed et al., reported a 1-year follow-up in a case with trans-styloid, trans-scaphoid, and trans-triquetral perilunate fracture-dislocation treated by open surgery ([6](#)). Sagini et al., also reported a patient with symptoms of ulnar nerve irritation with a transradial styloid perilunate dislocation ([9](#)).

Campbell reported a case of trans-scaphoid perilunate dislocation with styloid fracture ([8](#)). Wesley et al., studied an acute case of trans-scaphoid, trans-capitate, and trans-triquetral perilunate fracture-dislocation ([10](#)). Stevanovic et al., described an acute case of trans-scaphoid,

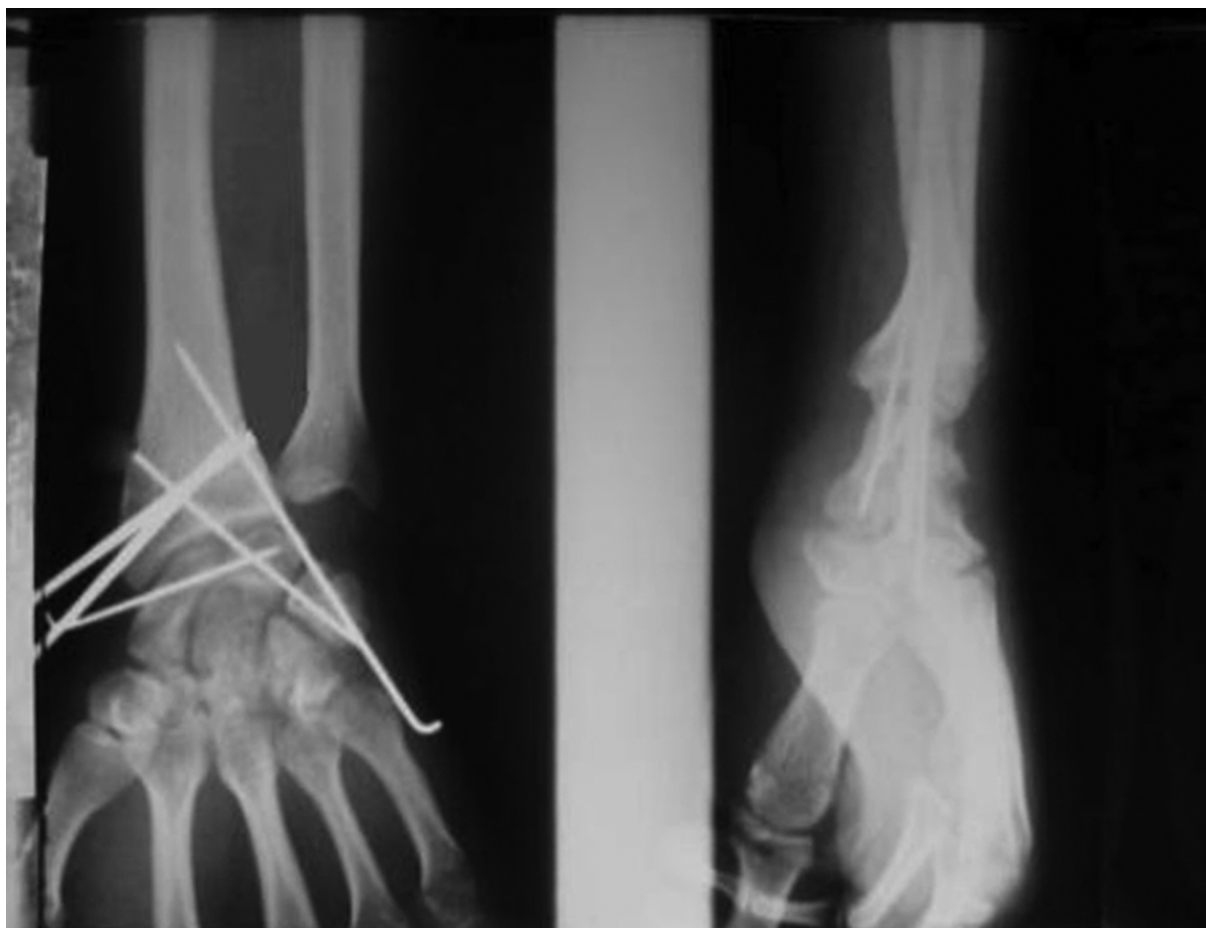


Figure 3. Postoperative Radiographs

trans-triquetral, and volar lunate fracture-dislocation of the wrist (11). Grissis et al., experimented on a neglected trans-scaphoid, trans-styloid, and volar dislocation of the lunate. In their case, they performed an open reduction as well as a fixation with K-wire applying a combination of dorsal and volar approach (12). The current study authors agree with them because according to their experience in such cases, it is not easy to reach an anatomic reduction just through volar approach. A unique feature of the current case was a combination of radial styloid fracture and perilunate dislocation without a fractured scaphoid. Many authors presumed that ligament repair was absolutely necessary to maintain the reduction as well as the restoration of carpal alignment to optimize the outcome. Despite a number of successful cases that opted for closed reduction, percutaneous fixation or open reduction are ultimately required to maintain the reduction (13, 14).

Virani et al., recommend prompt open reduction and

ligament repair or reconstruction for these types of injuries, but reports similar to their cases need to be confirmed by long-term outcome investigations; therefore, further long-term studies are needed to compare the degenerative carpal changes in patients treated percutaneously versus open reduction. It seems that based on the available literatures, surgical treatment of each type of perilunate dislocation can provide good clinical outcomes, allowing patients to return to normal activities in a reasonable timescale when delays to surgery are kept to a minimum and definitive fixation is comprised all fractures. In the current case, the reduction was anatomic and it was achieved noticeably short after the operation. Furthermore, authors could be relied upon to be in contact with the patient in case of any loss of reduction (15, 16).

In summary, a prompt diagnosis, an in time closed reduction, and also percutaneous pinning could result in a desirable treatment of such injuries.

References

1. Short WH, Werner FW, Green JK, Sutton LG, Brutus JP. Biomechanical evaluation of the ligamentous stabilizers of the scaphoid and lunate: part III. *J Hand Surg Am.* 2007;**32**(3):297-309. doi: [10.1016/j.jhsa.2006.10.024](https://doi.org/10.1016/j.jhsa.2006.10.024). [PubMed: [17336835](https://pubmed.ncbi.nlm.nih.gov/17336835/)].
2. Jain DCR, Murali S. Volar intercalated segmental instability in scaphoid non-union with lunotriquetral coalition: A case report. *The Int J Ortho Surg.* 2009;**18**(1).
3. J M. Mechanism of carpal injuries. *Clin Orthop Relat Res.* 1980;**149**:45-54.
4. Short WH, Werner FW, Green JK, Masaoka S. Biomechanical evaluation of ligamentous stabilizers of the scaphoid and lunate. *J Hand Surg Am.* 2002;**27**(6):991-1002. doi: [10.1053/jhsu.2002.35878](https://doi.org/10.1053/jhsu.2002.35878). [PubMed: [12457349](https://pubmed.ncbi.nlm.nih.gov/12457349/)].
5. Lichtman DBJ, Culp R, Alexander C. Palmar midcarpal instability: results of surgical reconstruction. 1993. *J Hand Surg Am*; **18**(2):307-15.
6. Majeed SA, Kumar SM. Transstyloid, transscaphoid, transtriquetral perilunate dislocation - A late presentation. *Indian J Orthop.* 2010;**44**(3):345-8. doi: [10.4103/0019-5413.65147](https://doi.org/10.4103/0019-5413.65147). [PubMed: [20697493](https://pubmed.ncbi.nlm.nih.gov/20697493/)].
7. Suzuki T, Sato K, Nakamura T, Toyama Y, Ikegami H. Radial perilunate trans-styloid trans-triquetrum fracture dislocation: a case report. *Hand Surg.* 2008;**13**(1):41-4. doi: [10.1142/S0218810408003803](https://doi.org/10.1142/S0218810408003803). [PubMed: [18711784](https://pubmed.ncbi.nlm.nih.gov/18711784/)].
8. Campbell RJ, Thompson TC, Lance EM, Adler JB. Indications for Open Reduction of Lunate and Perilunate Dislocations of the Carpal Bones. *J Bone Joint Surg Am.* 1965;**47**:915-37. [PubMed: [14318630](https://pubmed.ncbi.nlm.nih.gov/14318630/)].
9. Sagini D, Gilula LA, Wollstein R. Transradial radial perilunate: a case report. *Am J Orthop (Belle Mead NJ).* 2011;**40**(4):E64-6. [PubMed: [21731934](https://pubmed.ncbi.nlm.nih.gov/21731934/)].
10. Wesley MSBP. Transscaphoid, transcapitate, perilunate fracture dislocation of the wrist: A case report. *J Bone Joint Surg Am.* 1972;**54**:1073-8.
11. Stevanovic MSS, Filler BC. Transscaphoid, transtriquetral volar lunate fracture dislocation of the wrist. *J Bone Joint Surg Am.* 1996;**78**:1907-10.
12. Grissis PCA, Chalichlis B, Pournaran J. Neglected Transscaphoid, transstyloid volar dislocation of lunate. *J Bone Joint Surg Br.* 2006;**88**:676-80.
13. Siegert JJ, Frassica FJ, Amadio PC. Treatment of chronic perilunate dislocations. *J Hand Surg Am.* 1988;**13**(2):206-12. [PubMed: [3351243](https://pubmed.ncbi.nlm.nih.gov/3351243/)].
14. Muller T, Hidalgo Diaz JJ, Pire E, Prunieres G, Facca S, Liverneaux P. Treatment of acute perilunate dislocations: ORIF versus proximal row carpectomy. *Orthop Traumatol Surg Res.* 2017;**103**(1):95-9. doi: [10.1016/j.otsr.2016.10.014](https://doi.org/10.1016/j.otsr.2016.10.014). [PubMed: [27923762](https://pubmed.ncbi.nlm.nih.gov/27923762/)].
15. Virani SR, Wajekar S, Mohan H, Dahapute AA. A unique case of bilateral trans-scaphoid perilunate dislocation with dislocation of lunate into the forearm. *J Clin Orthop Trauma.* 2016;**7**(Suppl 1):110-4. doi: [10.1016/j.jcot.2016.04.003](https://doi.org/10.1016/j.jcot.2016.04.003). [PubMed: [28018087](https://pubmed.ncbi.nlm.nih.gov/28018087/)].
16. Griffin M, Roushdi I, Osagie L, Cerovac S, Umarji S. Patient-Reported Outcomes Following Surgically Managed Perilunate Dislocation: Outcomes After Perilunate Dislocation. *Hand (N Y).* 2016;**11**(1):22-8. doi: [10.1177/1558944715617222](https://doi.org/10.1177/1558944715617222). [PubMed: [27418885](https://pubmed.ncbi.nlm.nih.gov/27418885/)].