

Healing Effects of Synthetic Versus Commercial Alginate Hydrogel Dressings on Wounds

Hamid Babavalian,^{1,2} Ali Mohammad latifi,^{1*} Mohammad Ali Shokrgozar,³ Shahin Bonakdar,³

Fatemeh Shakeri,¹ and Hamid Tebyanian^{1,4}

¹Applied Biotechnology Research Center, Baqiyatallah University of Medical Sciences, Tehran, IR Iran

²Applied Virology Research Center, Baqiyatallah University of Medical Sciences, Tehran, IR Iran

³National Cell Bank of Iran, Pasteur Institute of Iran, Tehran, IR Iran

⁴Research Center for Prevention of Oral and Dental Disease, Baqiyatallah University of Medical Sciences, Tehran, Iran

*Corresponding author: Ali Mohammad latifi, Applied Biotechnology Research Center, Baqiyatallah University of Medical Sciences, Tehran, IR Iran. Tel: +98-2188617712, Fax: +98-2182482549, E-mail: amlatifi290@gmail.com

Received 2016 May 06; Revised 2016 July 03; Accepted 2016 August 07.

Abstract

Background: Hydrogels based on natural ingredients, such as alginate, are considered promising wound dressings. Alginic acid, a polysaccharide polymer, is a structural component of the cell walls of brown algae. The important features of alginates used in biological dressings include non-toxicity, biocompatibility, biodegradability, hydrophilicity, and excellent swelling behavior.

Objectives: In this study, the effects of alginate hydrogels and commercial alginate dressings were studied with regard to wound recovery in a rat model.

Methods: Fifteen Wistar rats were divided into three groups of five. One wound measuring 1 × 1 cm square was made on each rat using a template. One rat in each group was euthanized on the 4th, 7th, 14th, and 21st days, and skin samples were taken for histopathological analysis.

Results: The findings showed that the average total time of wound healing in the synthetic alginate dressing group was similar to that of the commercial dressing group. In this study, we found that synthetic alginate hydrogels were much more convenient for wound dressings and for the treatment of surface wounds.

Conclusions: The treatment outcomes showed that our synthetic alginate hydrogel dressing was highly promising as an alternative wound-healing system, opening a new path toward future research and development.

Keywords: Alginate Hydrogel, Dressing, Wound Healing

1. Background

Wound healing is a dynamic physiological process that is initiated and influenced by several factors. The process can be divided into four steps: hemostasis, inflammation, proliferation, and remodeling (1). Hydrogels based on natural materials are considered promising as wound-coverings due to their non-toxicity, biocompatibility, biodegradability, insolubility, hydrophilicity, and excellent swelling behavior (2). They can form flexible and strong covering materials that are penetrable to water vapor and metabolites, protecting wounds against bacterial infection (2). After the Second World War, the use of alginate dressings as hemostatic agents was reported both in vitro and in clinical studies. They were also used for wound healing initially in surgical wounds, then for accidents and in emergency departments (3, 4).

Alginate is a natural anionic and hydrophilic polysaccharide. It is one of the most abundant biosynthesized materials and is derived largely from brown sea-

weed and bacteria. Alginate contains blocks of (1-4)-linked β -D-mannuronic acid (M) and α -L-guluronic acid (G) monomers (5). Alginate is of interest for a wide range of applications as a biomaterial and especially as a supporting matrix or delivery system for tissue-healing and regeneration (5, 6).

Alginates are used in healthcare and are available on the market under several logos. They can be easily and rapidly prepared, making them appealing from an industrial point of view (7).

Alginate hydrogels are stable in acidic media, whereas they simply swell and fragment in alkaline media and in normal saline solution. Calcium ions are released during ion exchanges with sodium in the medium; electrostatic repulsion accelerates between the carboxylate anions, causing the swelling and erosion of the alginate gel (8, 9).

2. Objectives

On the basis of data reported in previous studies, we evaluated the wound-healing effects of a synthetic alginate-based hydrogel dressing in a rat model.

3. Methods

3.1. Alginate Hydrogel Synthesis

First, 0.6 g of alginate powder was added to 40 mL of ion-free water and mixed at 45°C and 600 rpm for 10 minutes until the solid compound dissolved. After dissolution, 0.225 g of liquid ethylene glycol was added to the alginate solution and stirred with a magnetic stirrer for 10 minutes at 200 rpm. Next, for degassing and complete evaporation of the solvent, the mixture was placed in a vacuum oven for 24 hours at 40°C. Then, 4% CaCl₂ solution was added to an alginate film in a Petri plate, the solution was removed, and the film was washed with ion-free water. Hydrogel films were placed in tubes containing 10 mL of phosphate buffered saline (PBS; pH = 7.4) at 37°C. Finally, the structure of the alginate hydrogel was characterized by Fourier-transform infrared (FTIR) (PerkinElmer, USA) and nuclear magnetic resonance (NMR) (Bruker, Germany) spectroscopy (10).

3.2. Toxicity Assessment of Synthesized Alginate Hydrogels

In this experiment, three different types of hydrogel, including agar, synthetic alginate hydrogels, and commercial alginate hydrogels, were investigated using 24-well plates (gel surface approximately 1 cm), with 20,000 cells after four days. This was performed in accordance with the standards ISO 10993-5 and directly (Direct) was performed. For the culture conditions, the incubator contained 5% carbon dioxide and 90% humidity, at a temperature of 37°C. Cell-culture plates were used as a negative control (non-response cytotoxicity).

Cell proliferation was used to evaluate toxicity with the MTT assay. For this test, 20,000 cells per sample were poured into 50 ml of serum-supplemented media. After three hours, the cells could be cultured on stick samples for adding to the sample surface for covering. This process was similar to that of the control sample. The cell-culture medium was removed after a specified time (three days) and 100 ml of MTT solution was applied to each well at a concentration of 0.5 mg/ml, then incubated at 37°C for 4 hours. Supernatants were removed and isopropanol was added to dissolve the purple crystals. The dissolved amount of material in isopropanol was identified at 570 nm with an ELISA reader (Convergent EL-Reader 96X, Germany). Wells with more cells showed higher optical density than in those with fewer cells. Thus, using a specific

equation, wells with much higher cell counts can be identified and compared with control samples. It should be noted that hydrogel substrates do not have the ability to attract and be stained with formazan, therefore, the MTT test did not have possible errors (11).

3.3. Animals

A total of 15 male Wistar rats (weight 180–200 g) were used in the present study. The animals were acclimatized to the laboratory conditions for one week prior to the onset of the experiment. The rats were individually caged, fed with commercial rat chow, and allowed water ad libitum. The experimental protocol was approved by the Institutional Animal Ethics Committee of the Pasteur Institute of Iran.

3.4. Experimental Group

The animals were randomly divided into three experimental groups of five rats each. The rats in the negative control group were not topically treated. The positive control group was treated topically with a commercial gel, and the third group was treated with the synthetic alginate hydrogel.

3.5. Experimental Design

The rats were anesthetized with intraperitoneal injections of ketamine hydrochloride (100 mg/kg body weight) and xylazine (10 mg/kg body weight) prior to the creation of the excision wounds (12). Briefly, the skin area was shaved one day prior to the experiment, and one full-thickness wound measuring 1 × 1 cm square was created on each rat with a template. The topical treatments continued for 21 days; the dressings were changed every two days. On days 4, 7, 14, and 21, one rat from each group was euthanized with an overdose of ether inhalation, and skin samples were taken for histopathological analysis.

3.6. Histopathological Analysis

For macroscopic assessment, the wound area was measured by taking a photograph of the outline of the wound every day, while the time required for healing was also measured (13). For microscopic assessment, skin samples were fixed in 10% formalin solution and embedded in paraffin. Tissue sections of 4–5 μm thickness were cut, then hematoxylin-eosin staining (H&E) and Masson's trichrome staining were performed. The wounds were evaluated for the extent of re-epithelialization, inflammation, angiogenesis, fibroblasts, collagen, and hair follicles.

3.7. Statistical Analysis

The non-parametric Friedman test was used to compare the groups. The level of statistical significance was $P < 0.05$.

4. Results

4.1. Synthetic Alginate Hydrogel

The prepared synthetic alginate gels and commercial alginate gels consisted of uniform transparent sheets of three-dimensional networks with a thickness of 3-4 mm. They showed good transparency to allow monitoring of the healing progress, as well as ensuring timely dressing alterations.

4.2. Toxicity Assessment of Synthesized Alginate Hydrogels

MTT cytotoxicity test samples were drawn for testing over a period of 3, 7, and 14 days on 3T3 cell fibroblast cells and charts. It can be seen in the comparison columns that all samples had an 80% higher survival rate within 3-14 days and all of the hydrogels lacked toxicity during this time period compared to the control samples. Commercial alginate hydrogels had a better situation to synthesized alginate hydrogels, but not at a level harmful to cells. The results are shown in Figure 1.

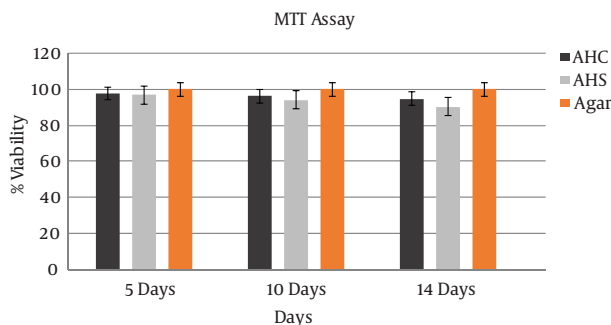


Figure 1. Cell proliferation with three different hydrogels based on fibroblast counts at 5, 10, and 14 days on the basis of MTT. *Assessments were conducted simultaneously with three separate tests ($P < 0.05$). AHC: alginate hydrogel commercial; AHS: alginate hydrogel synthetic.

4.3. Total Average Healing Time

The times for wound healing in the negative control group (A), commercial alginate hydrogel group (B), and synthesized alginate hydrogel group (C), respectively, were 9.4, 7.7, and 8 days. Based on the results, the average healing time in group B was lower than in the other groups. However, there was no statistically significant difference between groups B and C. The average healing time in group C was similar to that of group B. The results are shown in Figure 2.

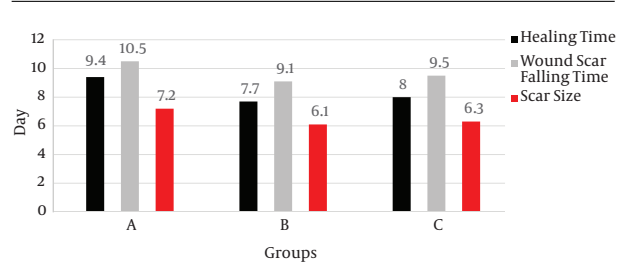


Figure 2. (A) Comparison of overall average time required for healing. (B) Comparison of scar formation times. (C) Comparison of scar size. *Results based on the independent third test were the same ($P < 0.05$).

4.4. Scar Formation Time

The commercial alginate hydrogel group (B) required the least time for scar formation, with an average of 9.1 days. The times for group A and group C were 10.5 and 9.5 days, respectively. Although the time until scar formation was lower in group B than in the other groups, it showed no significant difference with group C. The results are shown in Figure 2.

4.5. Remaining Scar Size

The measurement of remaining scar size was not statistically significantly different between groups. The commercial alginate hydrogel group had the smallest scars at 6.1 cm². Scars measured 7.2 cm² and 6.3 cm² in the negative control group and the synthesized alginate hydrogel group, respectively (Figure 2).

4.6. Angiogenesis

The peak period of vascularization was on day 7. Group B had the highest level of vascularization but did not show significant differences with group C (Figure 3).

4.7. Number of Fibroblasts

The number of fibroblasts were significantly different between the experimental groups at days 4, 7, and 14, but did not show significant differences at 21 days. The number of fibroblasts was the most increased on day 14. Group B had the highest number of fibroblasts, but this was not significantly different from group C (Table 1).

4.8. Hair Follicle Density

One of the indicators of the quality of wound healing is the regrowth of hair follicles. Follicular growth was not seen on days 4, 7, and 14, but was detected at 21 days. The average follicle numbers observed in each of the groups are shown in Figure 3.

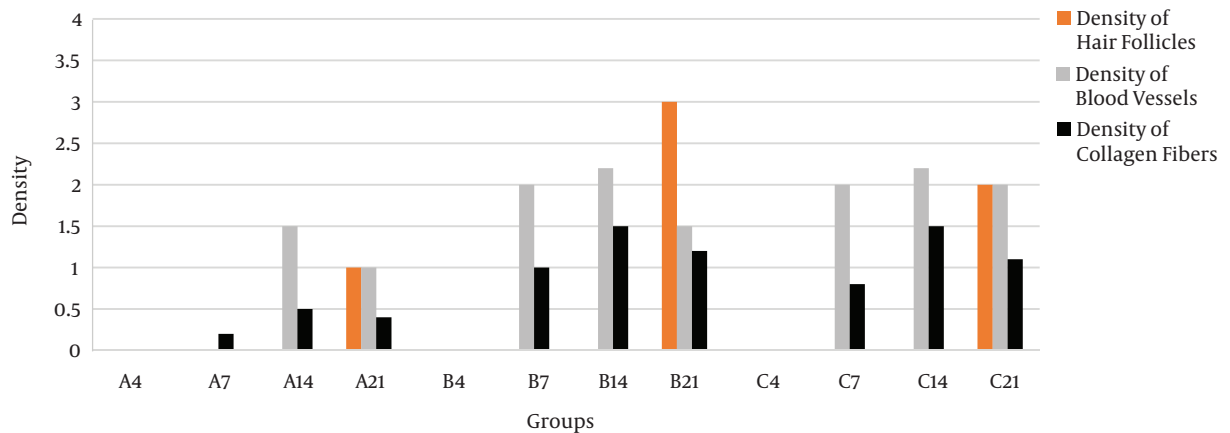


Figure 3. Statistical comparison of the density of hair follicles, numeric density of blood vessels, and density of collagen fibers in each group on days 4, 7, 14, and 21. *Results based on the independent third test are the same ($P < 0.05$).

Table 1. Statistical Comparison of Fibroblasts in Different Groups at 4, 7, 14, and 21 Days^a

Group and day	A4	A7	A14	A21	B4	B7	B14	B21	C4	C7	C14	C21
Fibroblasts	500	1200	2500	1200	550	2200	6500	2200	500	5500	7200	4700

^aResults based on the independent third test were the same ($P < 0.05$).

4.9. Epidermal Depth

Measurements of epidermal depth are effective for determining the degree of wound healing. These measurements were compared to normal skin tissue and expressed as percentages. The epidermal thickness was not calculated on day 4 because the epidermis was not fully formed and was not measurable. Groups B and C had much greater epidermal depth on days 7 and 14, compared to group A (Figure 4).

4.10. Collagen

The amount of collagen in the samples was measured and showed statistically significant differences on days 4, 7, and 14 in each group. No statistically significant difference was observed on day 21. Day 14 showed the most collagen growth, with group B having the highest level. Groups B and C did not show a statistically significant difference (Figure 3). Vascularization was shown with H&E staining on day 7 (Figure 5) and fibroblast growth was shown with H&E staining on days 7 and 14 (Figure 5).

5. Discussion

Significant skin damage from tissue lesions and the mechanisms of healing are important issues in the pharmaceutical and medical industries. Their importance is especially notable during disasters and crisis situations, such

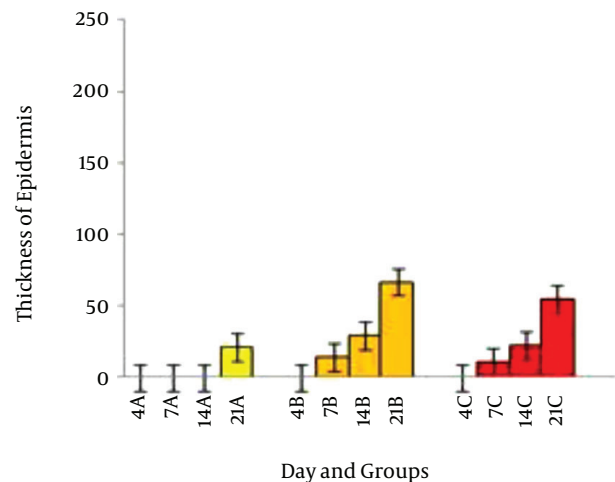


Figure 4. Thickness of epidermis different size groups at days 4, 7, 14, and 21. *Results based on the independent third test are the same ($P < 0.05$).

as in war zones, where appropriate treatment methods are required (14). Natural hydrogels are some of the most important and appropriate types of wound dressings. Natural hydrogel wound dressings are prepared from alginic acid and are widely used (15). Various studies have studied wound healing using these hydrogels. Freeman et al. evaluated the effects of sulfated alginate hydrogels on specific

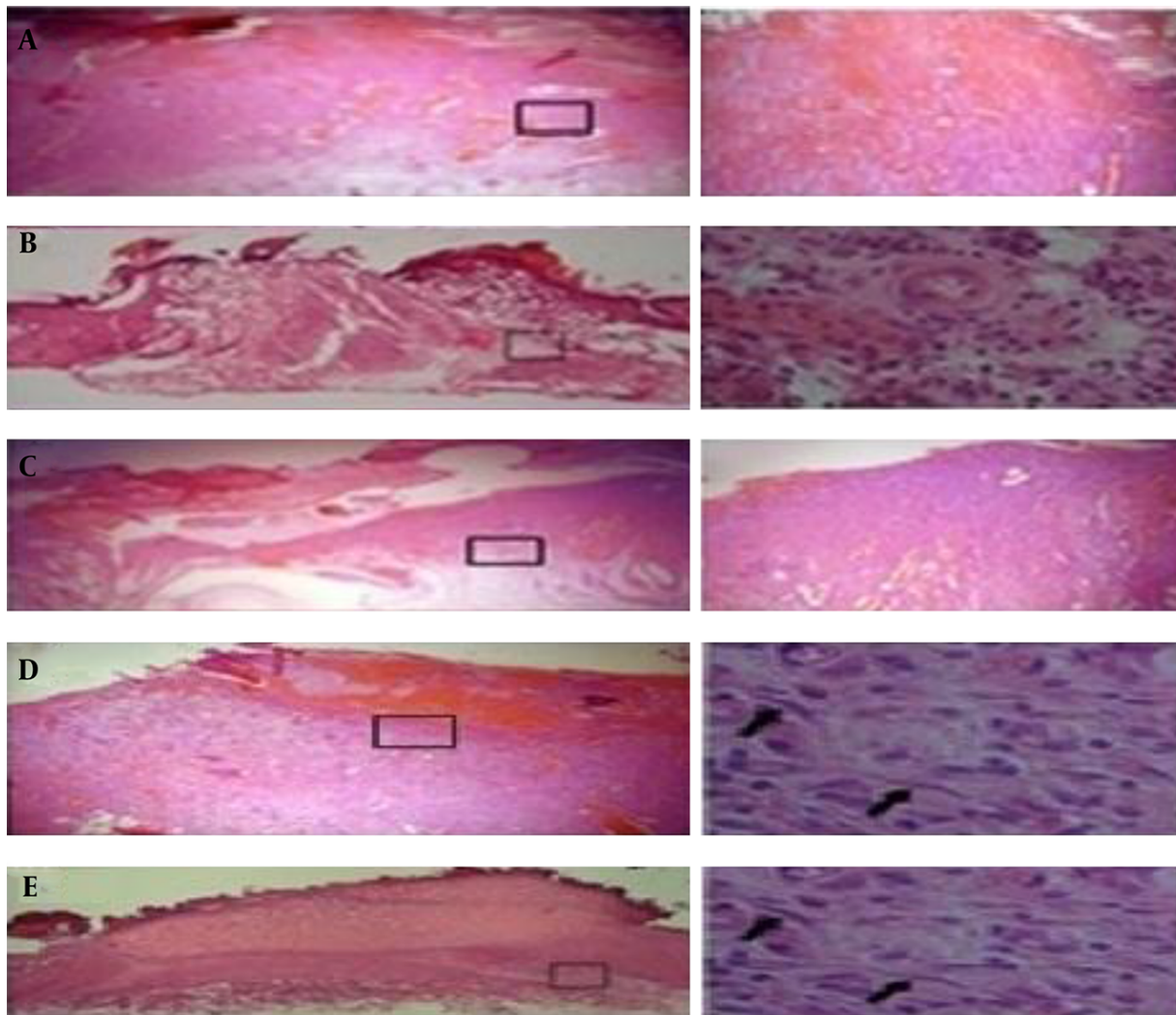


Figure 5. Transverse sections with a H&E staining at 7 days, representing vascularization. (A) Without treatment; (B) control (commercial alginate dressing); (C) synthesized alginate hydrogel; Transverse sections with H&E on days 7 and 14, representing increased fibroblast growth. (D) commercial alginate dressing; (E) synthesized alginate hydrogel.

binding and for the release of proteins that bind to heparin in wound healing (16). Jeon and colleagues evaluated growth factors while using alginate hydrogels, based on their affinity to heparin (17). Gupta et al. evaluated alginate hydrogels combined with aloe vera (18), while Babavalian et al. evaluated antibacterial peptide-containing sulfated alginate hydrogels in the healing of infected wounds (19). Nazeri and colleagues studied the effects of alginate hydrogels with honey (20), and Straccia assessed chitosan-alginate hydrogels (2). All of the results have suggested an important role for alginate hydrogel dressings in wound healing. According to the results obtained in the first step of the present research, commercial and synthesized algi-

nate hydrogels had the best results for all indicators examined. The statistical results of this study showed that day 4 indicates the inflammation stage of the wound-healing process. Synthesized and commercial alginate hydrogels resulted in the highest rates of recovery.

Our results clearly confirmed the positive impact of synthesized alginate hydrogels on skin wound healing. Synthesized and commercial alginate hydrogels had the shortest healing times, with a significant statistical difference compared to the negative control group ($P < 0.05$). Synthesized and commercial alginate hydrogels demonstrated the best results with regard to scar formation and scar size, showing significant differences with the negative

control group ($P < 0.05$). Microscopic studies confirmed all of the results. The synthesized and commercial alginate hydrogels showed a statistically significant difference with the negative control group with regard to vascular density and number of fibroblasts on days 4, 7, and 14 ($P < 0.05$).

Angiogenesis is necessary in wound healing, and scars are saturated with blood vessels (21). Angiogenesis uses granulation tissue, and vessel formation is a restructuring process. Angiogenic factors can stimulate and accelerate wound healing. Wound healing does not need vessel density in the inflammatory stage (22). Angiogenesis is also an important factor in the regeneration of skin. Research has shown that angiogenesis and granulation are increased in rats on day 7, but after that, these processes may be blocked. If blood vessels cannot be generated, fibroblast migration will be stopped and regenerative skin cannot be produced. Our results showed that the process of angiogenesis was increased in all groups. Synthesized and commercial alginate hydrogels showed decreased angiogenesis after 7 days. Thus, both accelerated and reduced blood vessel growth play important roles in wound healing. Synthesized and commercial alginate hydrogels showed the highest angiogenesis at day 7, and showed the best overall results. Epithelialization is an important factor in wound healing, and occurs due to the migration and division of epidermal cells. Epidermis reconstruction begins immediately after the injury and is almost complete in four weeks (23). The size of the newly formed epidermis was increased with the synthesized and commercial alginate hydrogels at day 7, and significant differences were clearly seen with the negative control group. These therapeutic properties indicate that synthetic alginate hydrogels have a great potential for treating and healing wounds.

5.1. Conclusion

Commercial alginate hydrogels showed relatively better results than synthesized alginate hydrogels, but there were no statistically significant differences between them. Synthesized alginate hydrogels were similar to commercial alginate hydrogels.

Acknowledgments

This study was extracted from a Ph.D. thesis, and approved and supported by the applied biotechnology research center, Baqiyatallah University of Medical Sciences, Tehran, Iran.

References

1. Boateng JS, Matthews KH, Stevens HN, Eccleston GM. Wound healing dressings and drug delivery systems: a review. *J Pharm Sci*. 2008;97(8):2892-923. doi: [10.1002/jps.21210](#). [PubMed: [17963217](#)].
2. Straccia MC, d'Ayala GG, Romano I, Oliva A, Laurienzo P. Alginate hydrogels coated with chitosan for wound dressing. *Mar Drugs*. 2015;13(5):2890-908. doi: [10.3390/md13052890](#). [PubMed: [25969981](#)].
3. Clark M. Rediscovering alginate dressings. *Wounds International*. 2012;3(1):1-4.
4. Van OJ, Gardner S. Wound dressings-classification and selection: an introduction to Tissue Viability Focus 2016. *Dermatological Nursing*. 2016;15(1):10-2.
5. Sun J, Tan H. Alginate-based biomaterials for regenerative medicine applications. *Materials*. 2013;6(4):1285-309.
6. Ching SH, Bansal N, Bhandari B. Alginate gel particles-a review of production techniques and physical properties. *Critical reviews in food science and nutrition*. 2015.
7. Nalamothu N, Potluri A, Muppalla MB. Review on marine alginates and its applications. *Journal of Pharm Research*. 2014;4(10).
8. Lee KY, Mooney DJ. Alginate: properties and biomedical applications. *Prog Polym Sci*. 2012;37(1):106-26. doi: [10.1016/j.progpolymsci.2011.06.003](#). [PubMed: [22125349](#)].
9. Schmitt A, Rodel P, Anamur C, Seeliger C, Imhoff AB, Herbst E, et al. Calcium alginate gels as stem cell matrix-making paracrine stem cell activity available for enhanced healing after surgery. *PLoS One*. 2015;10(3):0118937. doi: [10.1371/journal.pone.0118937](#). [PubMed: [25793885](#)].
10. Fan L, Jiang L, Xu Y, Zhou Y, Shen Y, Xie W, et al. Synthesis and anti-coagulant activity of sodium alginate sulfates. *Carbohydrate polymers*. 2011;83(4):1797-803.
11. Mosmann T. Rapid colorimetric assay for cellular growth and survival: application to proliferation and cytotoxicity assays. *J Immunol Methods*. 1983;65(1-2):55-63. [PubMed: [6606682](#)].
12. Gonca E. Comparison of thiopental and ketamine+xylazine anesthesia in ischemia/reperfusion-induced arrhythmias in rats. *Turk J Med Sci*. 2015;45(6):1413-20. [PubMed: [26775402](#)].
13. Khksari M, Rezvani ME, Sajadi MA, Soleimani A. The effect of topically applied water extract of *Rhazya stricta* on cutaneous wound healing in rats. *Koomesh*. 2000;1(3):1-10.
14. Borena BM, Martens A, Broeckx SY, Meyer E, Chiers K, Duchateau L, et al. Regenerative Skin Wound Healing in Mammals: State-of-the-Art on Growth Factor and Stem Cell Based Treatments. *Cell Physiol Biochem*. 2015;36(1):1-23. doi: [10.1159/000374049](#). [PubMed: [25924569](#)].
15. Calo E, Khutoryanskiy VV. Biomedical applications of hydrogels: A review of patents and commercial products. *European Polymer J*. 2015;65:252-67.
16. Freeman I, Kedem A, Cohen S. The effect of sulfation of alginate hydrogels on the specific binding and controlled release of heparin-binding proteins. *Biomaterials*. 2008;29(22):3260-8. doi: [10.1016/j.biomaterials.2008.04.025](#). [PubMed: [18462788](#)].
17. Jeon O, Powell C, Solorio LD, Krebs MD, Alsberg E. Affinity-based growth factor delivery using biodegradable, photocrosslinked heparin-alginate hydrogels. *J Control Release*. 2011;154(3):258-66. doi: [10.1016/j.jconrel.2011.06.027](#). [PubMed: [21745508](#)].
18. Gupta B, Agarwal R, Alam MS. Aloe vera loaded poly (vinyl alcohol)-poly (ethylene oxide)-carboxymethyl cellulose-polyester non-woven membranes. *J Biomater Tissue Eng*. 2013;3(5):503-11.
19. Babavalian H, Latifi AM, Shokrgozar MA, Bonakdar S, Mohammadi S, Moosazadeh Moghaddam M. Analysis of Healing Effect of Alginate Sulfate Hydrogel Dressing Containing Antimicrobial Peptide on Wound Infection Caused by Methicillin-Resistant *Staphylococcus aureus*. *Jundishapur J Microbiol*. 2015;8(9):28320. doi: [10.5812/jjm.28320](#). [PubMed: [26487923](#)].
20. Nazeri S, Ardakani EM, Babavalian H, Latifi AM. Evaluation of Effectiveness of Honey-Based Alginate Hydrogel on Wound Healing in a Mouse Model of Rat. *J Appl Biotechnol Rep*. 2015;2(3):293-7.

21. Demidova-Rice TN, Durham JT, Herman IM. Wound Healing Angiogenesis: Innovations and Challenges in Acute and Chronic Wound Healing. *Adv Wound Care (New Rochelle)*. 2012;**1**(1):17–22. doi: [10.1089/wound.2011.0308](https://doi.org/10.1089/wound.2011.0308). [PubMed: [24527273](https://pubmed.ncbi.nlm.nih.gov/24527273/)].
22. Johnson KE, Wilgus TA. Vascular Endothelial Growth Factor and Angiogenesis in the Regulation of Cutaneous Wound Repair. *Adv Wound Care (New Rochelle)*. 2014;**3**(10):647–61. doi: [10.1089/wound.2013.0517](https://doi.org/10.1089/wound.2013.0517). [PubMed: [25302139](https://pubmed.ncbi.nlm.nih.gov/25302139/)].
23. Pastar I, Stojadinovic O, Yin NC, Ramirez H, Nusbaum AG, Sawaya A, et al. Epithelialization in Wound Healing: A Comprehensive Review. *Adv Wound Care (New Rochelle)*. 2014;**3**(7):445–64. doi: [10.1089/wound.2013.0473](https://doi.org/10.1089/wound.2013.0473). [PubMed: [25032064](https://pubmed.ncbi.nlm.nih.gov/25032064/)].