

# Evaluation of Diaphragmatic Injuries in Patients With Negative Diagnostic Peritoneal Lavage and Penetrating Thoracoabdominal Trauma via Video-Assisted Thoracoscopy

Seyyed Hadi Mirhashemi,<sup>1</sup> Mahmood Ghahghaei,<sup>2</sup> Mohsen Soori,<sup>1</sup> Hassan Peyvandi,<sup>3,\*</sup> Omid

Shafagh-Sorkh,<sup>4</sup> Rezvan Azadi,<sup>5</sup> and Esmaeil Hajnasrollah<sup>6</sup>

<sup>1</sup>MD, Assistant Professor of General Surgery, School of Medicine, Shahid Beheshti University of Medical Sciences, Tehran, Iran

<sup>2</sup>MD, General Surgeon, Department of Surgery, Loghman Hakim Hospital, Shahid Beheshti University of Medical Sciences, Tehran, Iran

<sup>3</sup>MD, Associate Professor of General Surgery, Hearing Disorders Research Center, School of Medicine, Shahid Beheshti University of Medical Sciences, Tehran, Iran

<sup>4</sup>MSc, Associate Researcher, Hearing Disorders Research Center, Shahid Beheshti University of Medical Sciences, Tehran, Iran

<sup>5</sup>MD, Researcher, Shahid Beheshti University of Medical Sciences, Tehran, Iran

<sup>6</sup>MD, Full Professor of General Surgery, School of Medicine, Shahid Beheshti University of Medical Sciences, Tehran, Iran

\*Corresponding author: Hassan Peyvandi, MD, Associate Professor of General Surgery, Hearing Disorders Research Center, School of Medicine, Shahid Beheshti University of Medical Sciences, Tehran, Iran. Tel: +98-2151025182, Fax: +98-2155416130, E-mail: Hassan.peyvandi@gmail.com

Received 2016 July 04; Revised 2016 December 10; Accepted 2017 January 09.

## Abstract

**Background:** Diaphragmatic injuries due to penetrating trauma remain a diagnostic challenge. Inspection is the best approach in diagnosis as palpation may miss some injuries. The following approaches have been used, either alone or together, to recognize penetrating trauma injuries: physical examination, chest x-ray, computed tomography scan, focused assessment with sonography for trauma, and diagnostic peritoneal lavage (DPL). These modalities have been reported to miss 10 to 30 percent of injuries. These diagnostic tools have a low sensitivity and specificity to detect morbidities associated with these injuries. Finding a suitable diagnostic modality is essential for patient care. In this study, we assessed the diagnostic value of video-assisted thoracoscopy as an approach to diagnose diaphragmatic injuries in patients with negative DPL.

**Materials and Methods:** This case series was conducted on 33 patients with penetrating thoracoabdominal trauma referred to the Loghman Hospital in Tehran, Iran, from 2013 to 2014 (during an 18-month period). All negative DPL and hemodynamically stable hemopneumothorax patients with no indications for emergent surgical interventions were included in the study. All these patients underwent diagnostic thoracoscopy. Data were collected and analyzed by SPSS software version 20.

**Results:** Thirty-three patients were eligible to participate in this study with a mean age of  $23.79 \pm 6.42$  years. The youngest participant was 17 years old and the oldest was 51. A penetrating wound was located in the right side in 11 patients (33.3%) and on the left side in 19 subjects (57.6%). Three patients (9.1%) had trauma on both sides of their thorax. During thoracoscopy, 6 subjects (18.2%) were found to have asymptomatic diaphragmatic injuries.

**Conclusions:** Diaphragmatic injuries can be missed based on negative DPL. Application of video-assisted thoracoscopy is a minimally invasive procedure that is a practical approach for the evaluation, and management of trauma patients with diaphragmatic injuries.

**Keywords:** Penetrating Thoracoabdominal Trauma, Stab Wound, Diaphragmatic Injury, Thoracoscopy

## 1. Introduction

Diaphragmatic injuries are rare, comprising less than one percent of traumatic injuries (1, 2). Studies conducted on the National Trauma Data Bank (NTDB), the largest data bank in the world, reported the total incidence of diaphragmatic injuries to be 0.63% (1). These injuries are often accompanied by injuries of thoracic and abdominal organs. Although diaphragmatic injuries can be apparent in the acute phase (e.g. herniation of abdominal contents in chest X-ray), they can also be occult and imaging studies might not be able to diagnose these instances. A high level of clinical suspicion is critical in saving patients'

lives, especially given that a delay in diagnosis is often accompanied by an increased risk of herniation, strangulation of abdominal viscera and subsequent morbidity. In patients without definitive diagnosis, laparoscopy, thoracoscopy, or open surgical exploration may be necessary. Diaphragmatic injuries treated with open surgery or minimally invasive techniques are used based on the patient's general condition as well as the type of injuries (3).

Most diaphragmatic injuries occur due to trauma to the thoracoabdominal area. This region is superiorly bounded by the fourth intercostal space, posteriorly by the eighth intercostal space, laterally by the sixth intercostal

spaces and inferiorly by the costal margins (3).

The diaphragm can be directly injured via passage of sharp objects or missiles from the abdominal cavity into the chest or vice versa. Blunt trauma can also indirectly increase the pressure of the abdominal cavity and cause injury to the diaphragm. These injuries present either as large radial tears or small tears. In most cases, the smaller diaphragmatic injuries often not visible to the naked eye, making them difficult to recognize and treat (4).

Penetrating mechanisms, including stab wounds, gunshot and injuries from sharp objects comprise 65% of all diaphragmatic injuries (1). The remaining 35% are due to blunt traumas, 90% of which are caused by motor vehicle accidents and the rest are due to falling and pressing incidents (1, 4, 5).

Trauma patients may not exhibit signs and symptoms of diaphragmatic tears on arrival or their association injuries may be so severe that definitive evaluation of the diaphragm is postponed. Over time the tears expand and the risk of herniation increases, particularly on the left side. In a survey conducted on delayed diagnoses of diaphragmatic injuries, it was found that 3 of 16 patients had undiagnosed tears of the diaphragm (6).

Patients with gunshot wounds or stab wounds to the lower left thoracic region must be evaluated for diaphragmatic injuries via laparoscopy or diagnostic peritoneal lavage (DPL). In patients with positive DPL, abdominal assessment should be performed. In subjects with 1000 to 10 000 red blood cells per microliter in their DPL results, laparoscopy or thoracoscopy should be considered. Laparoscopy is preferred in patients with positive chest X-ray findings such as hemothorax or pneumothorax, or in subjects who cannot tolerate DPL (7). According to the available protocol for hemodynamically stable patients with thoracoabdominal penetrating injuries, one of the following measures is applied to treat patients: DPL, computed tomography (CT) scan, or observation (2).

The risk of diaphragmatic injuries in DPL negative patients who do not have an indication for emergent surgical interventions still exists (3). Therefore, we evaluated the diaphragmatic injuries in this group of patients using the video-assisted thoracoscopy.

## 2. Materials and Methods

In this case series, we identified 33 patients with thoracoabdominal stab wounds with hemopneumothorax and negative and positive DPL from 2013 to 2014. All of the patients had chest tube insertion upon admission. Hemodynamically stable patients underwent DPL. A positive DPL was regarded as RBC > 10 000/mL, WBC > 500/mL, amylase > 19 IU/L, alkaline phosphatase > 2 IU/L and bilirubin >

0.01 mg/dL. A negative DPL was found in those patients not requiring emergency surgical intervention.

We included patients with negative DPL in this study. Objectives, methods, advantages and disadvantages of the study were explained to the patients and consent was obtained from the patients prior to initiation of the study.

Inclusion criteria for the study population were as follows:

- 1- Patients with penetrating trauma by thoracoabdominal stab wounds
- 2- Being hemodynamically stable
- 3- Presence of hemopneumothorax
- 4- Normal abdominal exam
- 5- A negative DPL without any indications for emergent surgical interventions
- 6- Willing to participate

Exclusion criteria for the study population were as follows:

- 1- Patients with blunt trauma or penetrating trauma caused by gunshot or shotgun
- 2- Being hemodynamically unstable
- 3- Abdominal tenderness
- 4- Signs of peritonitis
- 5- Candidate for emergent surgical interventions
- 6- Not willing to undergo thoracoscopy

After receiving approval from the ethics committee of Loghman Hospital in Tehran, Iran, and obtaining written and signed consent from the patients, the survey was conducted according to the declaration of Helsinki. All of the subjects underwent diagnostic thoracoscopy under general anesthesia. After induction of anesthesia, a 10-mm port was inserted through the opening of the chest tube as the entrance route for the camera. Other ports were inserted according to the site of penetrating trauma through intercostal spaces, as needed. The superior surface of the diaphragm was carefully examined via video-assisted thoracoscopy and in cases of diaphragmatic injuries, tears were sutured when possible.

## 3. Results

During the 18-month period of patient recruitment, 33 subjects who met the inclusion criteria were included as the study population. The mean age of these patients was  $23.79 \pm 6.42$  years with a minimum age of 17 years and maximum age of 51 years.

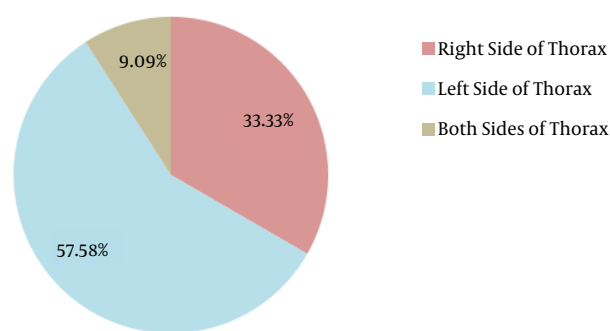
Stab wounds were located on the right side of the thorax in 11 patients and on the left side of the thorax in 19 patients. Three patients had stab wounds on both sides of the thorax (Figure 1).

Thoracoscopy revealed diaphragmatic injuries in 6 patients (18.2%) (Table 1).

**Table 1.** The Patients' Demographic Information

Patient No.	Patient Sex/Age	Location of Injury (Intercostal Space)	Size of Skin Wound, cm	Treatment
1	M/17	LT 6 <sup>th</sup>	5	Thoracoscopic repair
2	M/23	LT 7 <sup>th</sup>	4.5	Thoracoscopy + laparotomy
3	M/27	LT 6 <sup>th</sup>	3.5	Thoracoscopic repair
4	M/17	RT 6 <sup>th</sup>	4	Thoracoscopic repair
5	M/22	LT 6 <sup>th</sup>	6	Thoracoscopic repair
6	M/24	LT 5 <sup>th</sup>	4	Thoracoscopic repair

Abbreviations: M, male; LT, left thoracic; RT, right thoracic.

**Figure 1.** The Location of Stab Wounds in Study Patients

The first patient was a 17-year-old boy, who had penetrating trauma to the 6th intercostal space at the left side of the chest. The diaphragmatic tear was sutured using the thoracoscopic approach.

The second patient was a 23-year-old man with a 4.5 cm tear in the diaphragm caused by a stab wound to the 7th intercostal space at the left side. Due to herniation of the transverse colon and omentum through the defect and consequently strangulation, the patient underwent laparotomy with a midline incision for an abdominal approach.

The third case was a 27-year-old man with trauma to the 6th intercostal space at the left midclavicular line. A chest tube was placed and the laceration was sutured through the thoracoscopic approach.

The fourth patient was a 17-year-old boy with a stab wound to the 6th intercostal space on the right, which was treated by chest tube placement and surgical treatment through thoracoscopy.

The fifth patient was a 22-year-old man with a 6-cm tear in the diaphragm due to a stab wound to the 6th intercostal space at the left midclavicular line next to the sternum that was treated thoracoscopically.

The last subject was a 24-year-old man with trauma to

the 7th intercostal space at the left midclavicular line, sutured at the thoracoscopy session.

Other than these 6 patients, there was one other subject with a stab wound to the 5th intercostal space at the right anterior axillary line that caused a 1 cm partial-thickness laceration, which was left untreated. In the other 26 patients, the diaphragm was normal.

#### 4. Discussion

Diaphragmatic injuries, especially due to penetrating traumas, are still considered diagnostically challenging. Currently, the gold standard test is not available and palpation alone may result in missed diagnoses. In some cases, direct visualization is the optimal approach for confirming a diaphragmatic injury, but this approach has not been used routinely.

In this study, we evaluated 33 hemodynamically stable patients with thoracoabdominal penetrating traumas without any indications for emergency surgical interventions by video-assisted thoracoscopy. In 6 patients, diaphragmatic injuries were revealed and 5 of them were successfully treated through the thoracoscopic approach. In 6 (18.2%) of the patients who had negative DPL with no confirmation of diaphragmatic injuries, the lacerations of diaphragm were found by thoracoscopy (Table 1).

Physical examination, chest X-ray, CT scans, focused assessment with sonography in trauma (FAST) and DPL, either alone or together, do not provide sufficient sensitivity and specificity as diagnostic tools. With these methods, 10% to 30% of the cases may be missed (8). Chest radiography might show a nonspecific hemothorax. Despite the vast improvements in CT scan imaging, this method still lacks sensitivity and is not available for everyone. Due to the poor blood supply of diaphragm, identification of the small amount of blood by FAST and DPL is very difficult (9, 10). Regarding the low sensitivity of available diagnostic tools and the morbidity and mortality associated

with delayed diagnosis of diaphragmatic injuries, some researchers insist on the necessity of abdominal exploration for all the patients with thoracoabdominal penetrating wounds (8). Laparotomy is negative in 20% - 40% of the patients (10-12).

In patients with thoracoabdominal penetrating traumas without any indications for laparotomy or thoracotomy, thoracoscopy is a suitable tool for evaluation of diaphragmatic lacerations, providing a good visualization of the total surface of diaphragm and needless of insufflation. Laparoscopy is also a good diagnostic tool; being preferred by some researchers (13). Nevertheless, visualization provided by thoracoscopy is better than laparoscopy, especially in the right side and posterior regions. Also, in some instances pressure pneumothorax following CO<sub>2</sub>-gas insufflation for laparoscopy has been reported (14).

Application of the video-assisted thoracoscopy for diagnosis of diaphragmatic injuries in penetrating wounds has been reported (2). This method is well-tolerated and is considered relatively noninvasive. The sensitivity of 98% - 100%, specificity of 90% - 98%, and diagnostic precision of 94% - 100% have been reported (2). In one survey, the missing rate of this method was reported to be 4% (9, 15, 16). Moreover, the hemithorax including lung parenchyma and mediastinum is clearly visualized. Blood and clots in the pleural space can be easily removed and chest tube can be placed under direct observation. These maneuvers decrease late complications (3).

Complete observation of the diaphragm is possible when the scope is entered through the 4th and 5th intercostal spaces. This space is usually one level higher than when thoracoscopy is performed for other purposes. When an injury is identified, it is suggested for the patient to undergo complete diagnostic abdominal laparotomy since a significant risk of concomitant injuries is present (12).

#### 4.1. Conclusion

According to the results of this study, diaphragmatic injuries cannot be ruled out based on a negative DPL. Considering the importance of early diagnosis and possible complications of occult diaphragmatic injuries, application of the video-assisted thoracoscopy as a minimally invasive procedure may be appropriate for evaluation and management of these traumas, especially in patients with hemopneumothorax for whom a chest tube has been placed.

#### Acknowledgments

We would like to thank the Clinical Research Development Center of Loghman Hakim Hospital, Shahid Beheshti

University of Medical Sciences, Tehran, Iran.

#### Footnotes

**Conflict of Interest:** There is no actual or potential conflict of interest in relation to this article.

**Funding Disclosure:** No relevant financial relationship exists.

#### References

- Fildes J. National trauma data bank. *Encyclopedia of Intensive Care Medicine*. Springer; 2012. pp. 1510-3.
- Mattox K, Moore E, Feliciano D. *Trauma*. seventh edition ed. McGraw-Hill Education; 2012.
- Parreira JG, Rasslan S, Utiyama EM. Controversies in the management of asymptomatic patients sustaining penetrating thoracoabdominal wounds. *Clinics (Sao Paulo)*. 2008;**63**(5):695-700. [PubMed: 18925332].
- Hedblom CA. Diaphragmatic Hernia. *J Am Med Assoc*. 1925;**85**(13):947. doi: 10.1001/jama.1925.02670130009003.
- Rodriguez-Morales G, Rodriguez A, Shatney CH. Acute Rupture of the Diaphragm in Blunt Trauma: Analysis of 60 Patients. *J Trauma: Injury Infect Crit Care*. 1986;**26**(5):438-44. doi: 10.1097/00005373-198605000-00005.
- Feliciano DV, Cruse PA, Mattox KL, Bitondo CG, Burch JM, Noon GP, et al. Delayed Diagnosis of Injuries to the Diaphragm after Penetrating Wounds. *J Trauma: Injury Infect Crit Care*. 1988;**28**(8):1135-44. doi: 10.1097/00005373-198808000-00005.
- Brunicaardi F, Andersen D, Billiar T, Dunn D, Hunter J, Matthews J, et al. *Schwartz's Principles of Surgery*. 10th edition ed. McGraw-Hill Education; 2014.
- Madden MR, Paull DE, Finkelstein JL, Goodwin CW, Marzulli V, Yurt RW, et al. Occult Diaphragmatic Injury from Stab Wounds to the Lower Chest and Abdomen. *J Trauma: Injury Infect Crit Care*. 1989;**29**(3):292-8. doi: 10.1097/00005373-198903000-00003.
- Lowdermilk GA, Naunheim KS. Thoracoscopic Evaluation and Treatment of Thoracic Trauma. *Surg Clin North America*. 2000;**80**(5):1535-42. doi: 10.1016/s0039-6109(05)70243-7.
- Ochsner MG, Rozycki GS, Lucente F, Wherry DC, Champion HR. Prospective Evaluation of Thoracoscopy for Diagnosing Diaphragmatic Injury in Thoracoabdominal Trauma: A Preliminary Report. *J Trauma: Injury Infect Crit Care*. 1993;**34**(5):704-10. doi: 10.1097/00005373-199305000-00013.
- Lang-Lazdunski MDL, Mouroux MDJ, Pons MDF, Grosdidier MDG, Martinod MDE, Elkai "m MDD, et al. Role of Videothoracoscopy in Chest Trauma. *Annals Thoracic Surg*. 1997;**63**(2):327-33. doi: 10.1016/s0003-4975(96)00960-5.
- Uribe RA, Pachon CE, Frame SB, Enderson BL, Escobar F, Garcia GA. A Prospective Evaluation of Thoracoscopy for the Diagnosis of Penetrating Thoracoabdominal Trauma. *J Trauma: Injury Infect Crit Care*. 1994;**37**(4):650-4. doi: 10.1097/00005373-199410000-00020.
- Murray JA, Demetriades D, Asensio JA, Cornwell EE, Velmahos GC, Belzberg H, et al. Occult injuries to the diaphragm: prospective evaluation of laparoscopy in penetrating injuries to the left lower chest. *J American Coll Surg*. 1998;**187**(6):626-30. doi: 10.1016/s1072-7515(98)00246-4.
- Milfeld DJ, Mattox KL, Beall AC. Early evacuation of clotted hemothorax. *American Jf Surg*. 1978;**136**(6):686-92. doi: 10.1016/0002-9610(78)90336-7.
- Nel JH, Warren BL. Thoracoscopic evaluation of the diaphragm in patients with knife wounds of the left lower chest. *Br J Surg*. 1994;**81**(5):713-4. [PubMed: 8044556].

16. Villavicencio RT, Aucar JA, Wall MJ. Analysis of thoracoscopy in trauma. *Surg Endosc.* 1999;**13**(1):3-9. [PubMed: [9869678](#)].