

Recovery of Facial Nerve Paralysis After Temporal Nerve Reconstruction: A Case Report

Mohammad Reza Emamhadi¹ and Davood Mahmoudi^{1,*}

¹Brachial Plexus and Peripheral Nerve Injury Center, Department of Neurosurgery, Guilan University of Medical Sciences, Rasht, IR Iran

*Corresponding author: Davood Mahmoudi, Brachial Plexus and Peripheral Nerve Injury Center, Department of Neurosurgery, Guilan University of Medical Sciences, Rasht, IR Iran. Tel: +98-9121399790, Fax: +98-133331472, E-mail: drdmahmoudi@yahoo.com

Received 2014 May 28; Revised 2014 August 7; Accepted 2014 August 16.

Abstract

Introduction: Facial paralysis is common following accidents, trauma, viral infection or tumors.

Case Presentation: A 24-year-old male patient was referred to us with a history of sharp penetrating trauma to the right temporal region causing unilateral paralysis of the muscles of the right forehead. He was unable to scowl or elevate his right eyebrow and there were no folds on his right forehead. Anastomosis of branches of the temporal nerve was done one month after trauma following regular physical therapy sessions, outcome was good and paralysis of the muscles of the right forehead improved after several months.

Conclusions: Immediate repair of the facial nerve injury will improve the process of recovery and rehabilitation of the face and forehead muscles and may play a very important role in the patient's mental satisfaction and improve their quality of life.

Keywords: Facial Nerve Paralysis, Temporal Nerve Reconstruction, Temporal Penetrating Trauma

1. Introduction

1.1. Facial Nerve Paralysis

Facial paralysis is common following accidents, trauma, virus infection or tumors. Facial paralysis will affect the patient psychologically, and may cause depression and anxiety. In this report, we present a case of a young man with unilateral paralysis of the muscles of the forehead caused by penetrating trauma who recovered after repair of the temporal branch of the facial nerve. Nerve repair was done one month after trauma and recovery was good 3 months later.

1.2. Facial Nerve

The facial nerve, cranial nerve VII, is a complex peripheral nerve (motor-sensory-secretory) which has a large motor branch and a smaller sensory one.

The nerve is damaged more than the other cranial nerves. The pathways of the facial nerve are variable and run from the skull base to the face. This nerve passes inside the temporal bone and through the internal auditory canal beside the vestibulocochlear nerve. In the extracranial part of the pathway in the parotid gland, the facial nerve divides into 5 branches that innervate 14 of the 17 paired muscle groups of the face. The distal portion of the facial nerve include the cervical branch, mandibular branch, buccal branch, zygomatic branches, temporal branches and posterior auricular branch.

1.3. Temporal Nerve (Frontal Nerve)

The temporal branch of the facial nerve (frontal branch of the facial nerve) crosses the zygomatic arch in the temporal region, supplying the auriculares anterior and superior. The more anterior branches supply the frontalis, the orbicularis oculi, and corrugator supercilii and muscles. To test the function of the temporal branches of the facial nerve, the patient is asked to frown and wrinkle his or her forehead.

2. Case Presentation

A 24-year-old male patient was referred to us with a history of sharp penetrating trauma to the right temporal region causing unilateral paralysis of the muscles of the right forehead. He was unable to scowl or elevate his right eyebrow and there were no folds on his right forehead. Anastomosis of branches of the temporal nerve was done one month after trauma following regular physical therapy sessions, outcome was good and paralysis of the muscles of the right forehead improved after several months (Figure 1).

2.1. Management and Results

The right frontalis, orbicularis oculi and corrugator supercilii muscles were paralyzed. Electromyography was done 3 weeks after trauma and complete severance of the temporal nerve branch of the facial nerve was reported. The temporal nerve repair was done one month after trauma.

2.2. Surgical Technique

The nerve ends (Figure 2) were found and end to end anastomosis and suturing with 10/0 nylon were done. Wound closure with done using 4/0 nylon (Figure 3).

Facial rehabilitation via physical therapy sessions. Outcome was good and paralysis of the muscles of the right forehead improved after several months (Figure 4).

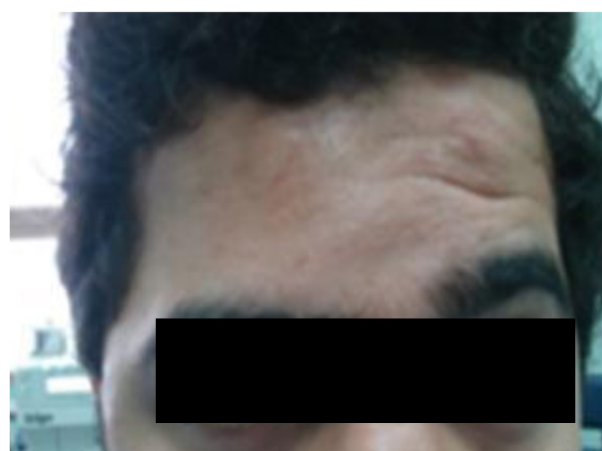
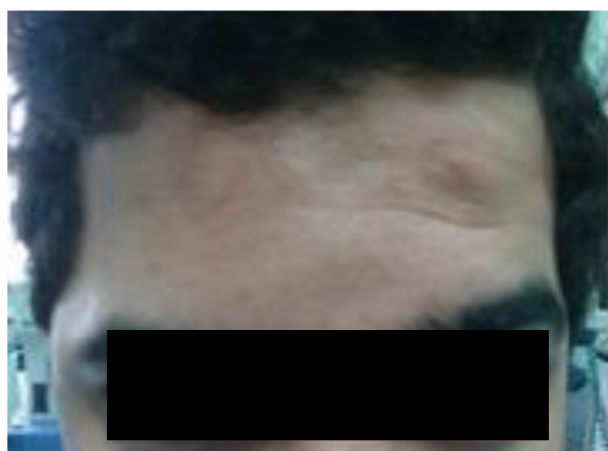
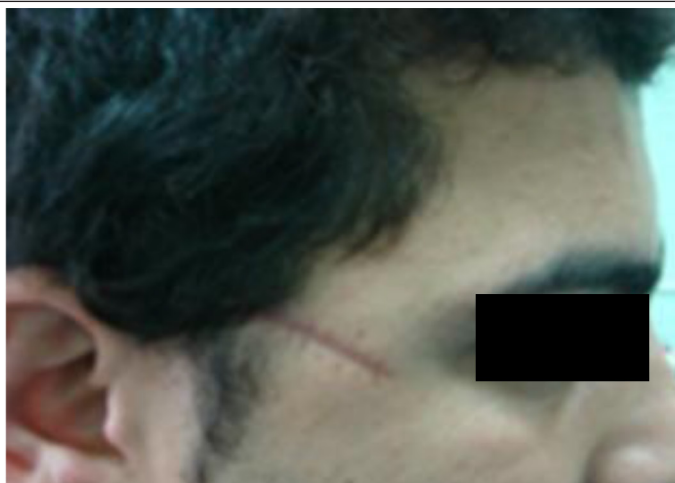Figure 1. Preoperative Right Forehead

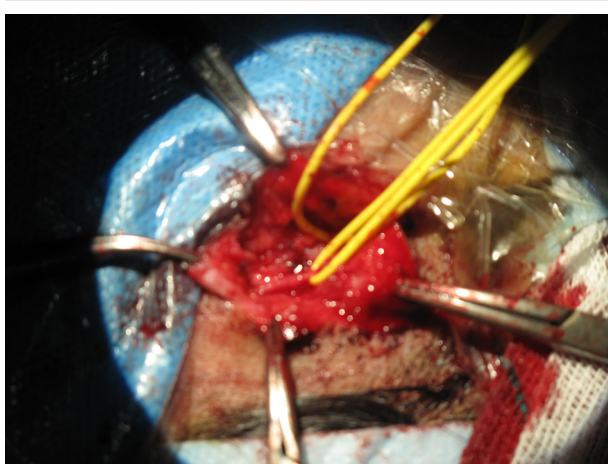


Figure 2. Dissection to Find the Nerve Ends

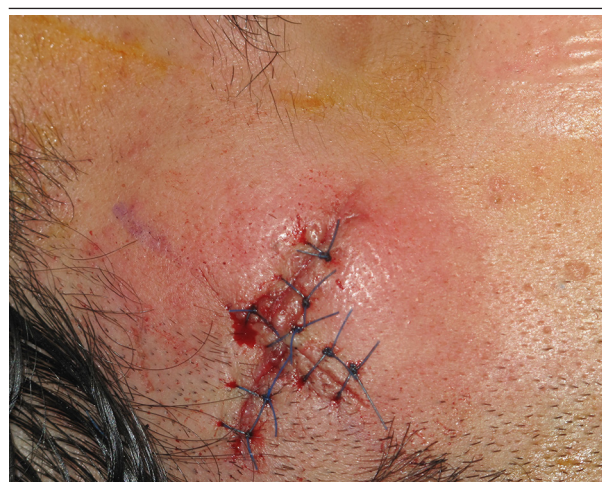

Figure 3. Wound Closure After Anastomosis

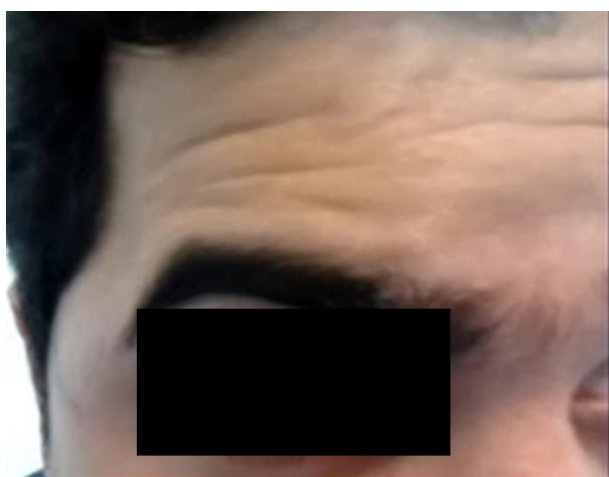

Figure 4. Postoperative View of the Right Forehead

3. Discussion

The facial nerve is exposed to many traumatic injuries because of its superficial location; paralysis of the muscles of the brow and forehead are unfavorable complications (1-3). Also, there are some reports of iatrogenic causes of the temporal nerve injury due to craniofacial or dermatological surgery (4-6). Thus, the temporal area should be considered as a danger zone during the surgery of the face. Immediate repair of the nerve injury will

improve the process of recovery and rehabilitation of the face and forehead muscles and may play a very important role in the patient's emotional and mental status and change their quality of life, especially in young patients.

Footnote

Authors' Contribution: Study design and supervision: Mohammad Reza Emamhadi. Patient management: Davood Mahmoudi.

References

1. Salas E, Ziyal IM, Bejjani GK, Sekhar LN. Anatomy of the fronto-temporal branch of the facial nerve and indications for interfascial dissection. *Neurosurgery*. 1998;**43**(3):563-8. [PubMed: 9733311]
2. Zani R, Fadul RJ, Da Rocha MA, Santos RA, Alves MC, Ferreira LM. Facial nerve in rhytidoplasty: anatomic study of its trajectory in the overlying skin and the most common sites of injury. *Ann Plast Surg*. 2003;**51**(3):236-42. doi: 10.1097/01.SAP.0000063755.42122.5F. [PubMed: 12966233]
3. Schmidt BL, Pogrel MA, Hakim-Faal Z. The course of the temporal branch of the facial nerve in the periorbital region. *J Oral Maxillofac Surg*. 2001;**59**(2):178-84. doi: 10.1053/joms.2001.18271. [PubMed: 11213986]
4. Hendi A. Temporal nerve neuropraxia and contralateral compensatory brow elevation. *Dermatol Surg*. 2007;**33**(1):114-6. doi: 10.1111/j.1524-4725.2007.33020.x. [PubMed: 17214691]
5. Dahlke E, Murray CA. Facial nerve danger zone in dermatologic surgery: temporal branch. *J Cutan Med Surg*. 2011;**15**(2):84-6. [PubMed: 21477555]
6. Flynn TC, Emmanouil P, Limmer B. Unilateral transient forehead paralysis following injury to the temporal branch of the facial nerve. *Int J Dermatol*. 1999;**38**(6):474-7. [PubMed: 10397591]