

# Re-Contouring Interpositional Gap Arthroplasty with Ramus Height Preservation for Treatment of Temporomandibular Joint Ankylosis: Case Report (New Technique)

Fahimeh Akhlaghi<sup>1 \*</sup>, Maryam Rezaei Majd<sup>2</sup>

<sup>1</sup>Associate Professor, Department of Oral and Maxillofacial Surgery, Dental School, Shahid Beheshti University of Medical Sciences, Tehran, Iran

<sup>2</sup> Student of Dentistry, Dental School, Shahid Beheshti University of Medical Sciences, Tehran, Iran

\* **Corresponding Author:** Department of Oral and Maxillofacial Surgery, Dental School, Shahid Beheshti University of Medical Sciences, Tehran, Iran. Email: [fahimehakhlaghi@yahoo.com](mailto:fahimehakhlaghi@yahoo.com)

Received June 8, 2019; Accepted August 28, 2019; Online Published January 01, 2020

## Abstract

**Background:** Ankylosis of the temporomandibular joint (TMJ) is an intracapsular union between the mandibular condylar disc and the temporal articular surface that restricts mandibular functions. The management of TMJ ankylosis requires minimally invasive methods.

**Objectives:** This study aims to present a new surgical method for restoring ramus height as much as possible after condylectomy of the TMJ due to ankylosis.

**Case Presentation:** Two patients with TMJ ankylosis participated in this investigation. Patients' preoperative maximal mouth openings were 3 mm and 9 mm. A new method was used to separate the bony fusion between the condyle and the glenoid fossa. Then, the condylar head on the mandibular ramus was recontoured, and finally the temporalis musculofascial flap was employed as an interpositional graft. Patients were followed for six months. Both surgeries were performed at the Department of Oral and Maxillofacial Surgery of Taleghani Hospital, Shahid Beheshti University of Medical Science, Tehran, Iran.

**Results:** Both patients had an average maximal mouth opening of 35-40 mm postoperatively.

**Conclusion:** In patients who have TMJ ankylosis the excessive bone between the condyle and the zygomatic arch can be removed by releasing the ankylotic site followed by routine gap arthroplasty so that the ramus becomes shorter than the other side. With this method, however, the condylar head is also recontoured, thus preserving more ramus length than with other techniques; future orthognatic surgery or distraction osteogenesis (DO), if necessary, will also be easier.

**Keywords:** Temporomandibular joint ankylosis, Gap arthroplasty, Interpositional arthroplasty, Orthognatic surgery, Distraction osteogenesis (DO).

## Introduction

Ankylosis is a Greek term meaning "stiff joint" (1). When occurring in the jawbone, ankylosis limits jaw movement and mastication. Ankylosis of the temporomandibular joint (TMJ) is an intracapsular union between the mandibular condylar disc and the temporal articular surface that restricts mandibular functions (2).

TMJ ankylosis is classified into three types. One type is intra- or extra-articular ankylosis, as reported by Kazanjian (1938) (3). A second type includes a bony, fibrous, fibro-osseous, and complete (<5 mm) or incomplete (>5 mm) maximum interincisal opening (3,4). The third classification, presented by Rowe, is based on the location, type of tissue involved, and the extent of the fusion (1).

Some reasons for TMJ ankylosis are trauma, infection, autoimmune disease, rheumatoid arthritis, irradiation, previous surgical therapy on TMJ, delayed treatment of condylar fractures, relative ankylotic gene (3-6), and, the

cause with the lowest percentage of occurrence, congenital deformity (7). These etiologic factors result in fusion of the mandible to the base of the skull (8-10), causing a frozen area in the joint space (11).

Clinically, ankylosis can lead to facial asymmetry, airway problems, difficulty in mastication, speech impairment, poor oral hygiene, and problems in normal facial growth which result in facial asymmetry (especially in children) or mandibular micrognathia. It may also cause difficulties in breathing, especially during sleep (2-4,10,12,13). The treatment of TMJ ankylosis is seriously difficult, because it depends on technique and has a high incidence of recurrence (2,5,14).

The management of TMJ ankylosis requires minimally invasive methods. At present, the surgical procedures mainly used for the treatment of ankylosis are 1) gap arthroplasty, 2) interpositional gap arthroplasty, or 3) reconstruction, if needed (15,16).

## Objectives

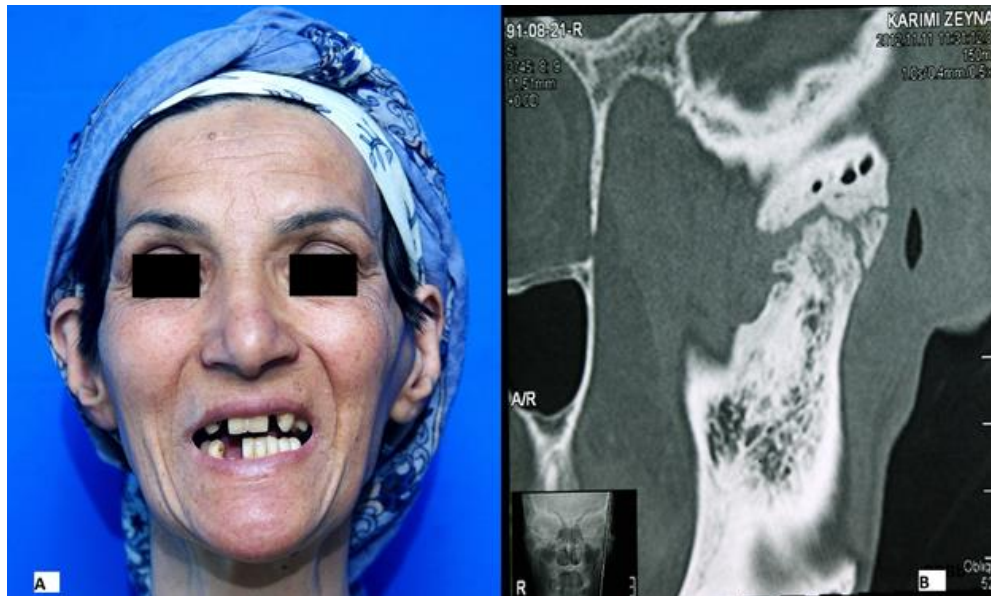
The current study aims to introduce a procedure to minimize reduction of the vertical height of the ramus and recreate the condylar head to near-normal.

## Cases Presentation

This report introduces two patients with unilateral traumatic temporomandibular joint ankylosis with a history

of trauma due to falling down who were referred to the Department of Oral and Maxillofacial Surgery of Shahid Beheshti University of Medical Science. Diagnosis data was collected by clinical examination and CT scan (axial and coronal), and panoramic radiography examination showed extensive bony ankylosis in both patients.

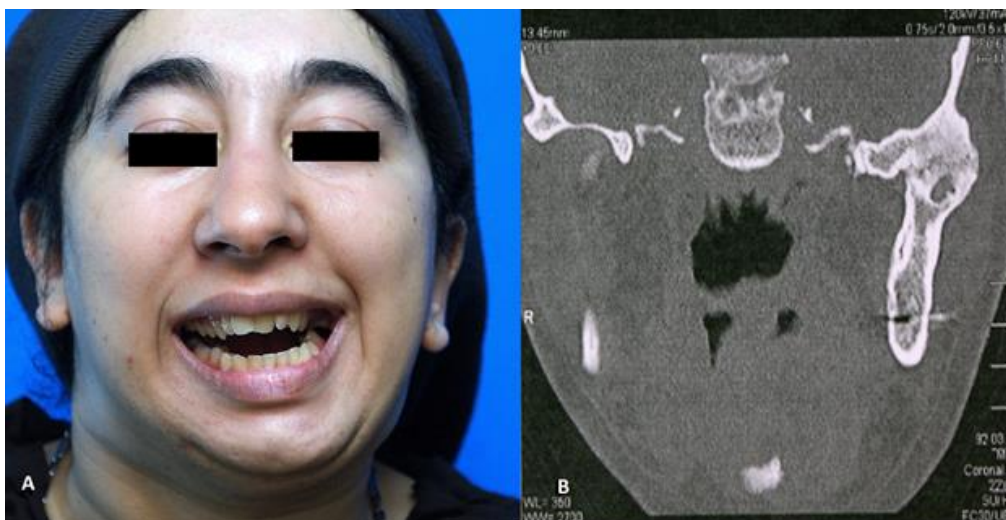
The first case was a 52-year-old female with TMJ ankylosis in her left mandible. The patient's maximum mouth opening (MMO) was 3 mm (Figure-1).



**Figure-1.** A: Photograph of a 52 years old woman with left sided TMJ ankylosis. B: Preoperative frontal view CT scan of the same patients.

The second case was a 22-year-old female who had limited mouth opening from birth. The patient had undergone interpositional gap arthroplasty and reconstruction in her left TMJ by costochondral graft as an initial surgical treatment when she was 7 years old, but the limitation in her mouth opening gradually reappeared due to unilateral

reankylosis. When she referred to our hospital, her maximal mouth opening was 9 mm, and she was experiencing problems consuming a normal diet and with normal jaw function; thus, she was seeking (and needed) retreatment (Figure-2).



**Figure-2.** A: Photograph of a 22 years old woman who presented with left sided TMJ ankylosis. B: Preoperative frontal view CT scan of the same patients.

### Surgical technique

Both patients underwent general anesthesia with nasotracheal intubation via fiber-optic technique which is carried out routinely. The TMJ region was accessed by performing a preauricular incision as described by Al-Kayat and Bramley.

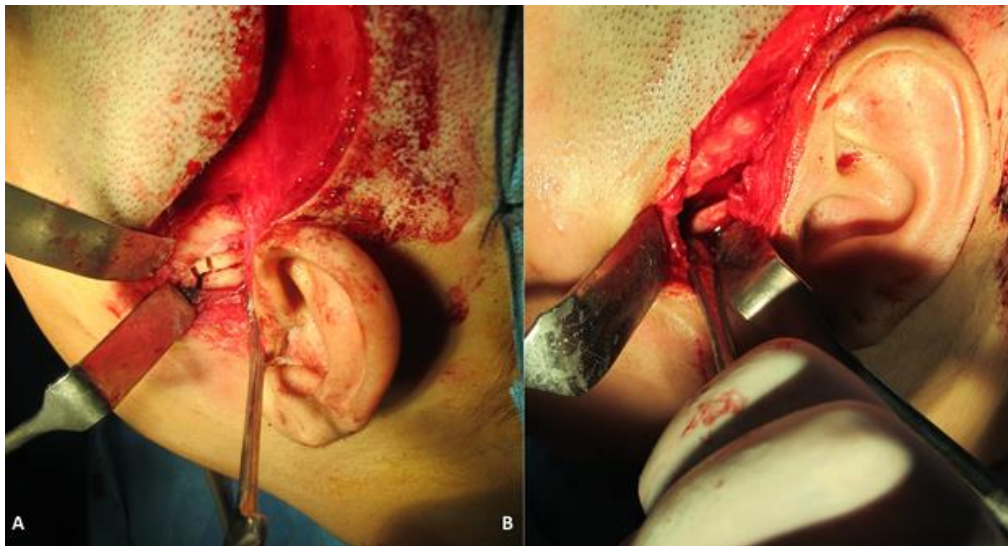
After exposing and identifying the site of the ankylotic bony mass, a condylar pattern was marked on the inferior border of the zygomatic arch, and the superior edge of the imaginary condyle was marked on the exposed bone. Excess bone between the two painted lines were removed with round and fissure carbide burs and osteotomes, and a gap was created at least 6 to 7 mm between the new condylar stump and the roof of the fossa. In this way, the ankylosis area was released (Fig. 3). Mouth opening tests were performed during the procedures. Coronoidectomy was not needed in the first

case, but in the second case, because a passive mouth opening of at least 30 mm intraoperatively was not achieved, ipsilateral and contralateral coronoidectomy was considered for the patient.

The temporal musculofascial flap was turned over the zygomatic arch and placed into the new glenoid fossa, then routinely sutured medially and posteriorly to the adjacent tissue in both patients.

An intraoperative mouth opening of 40 mm was achieved passively in both cases, and the surgeries were considered successful.

A suction drain was applied on the surgical field, and after copious irrigation, the muscle layers were closed using 3-0 polyglycolic acid in 2 layers, and the skin closure was sutured with 5-0 nylon. A pressure dressing was placed on the objective site.



**Figure-3.** Intra operatively photograph: A: Section of bony mass between two lines. B: Created a gap and release the condyle.

### Postoperative management

The suction drains were removed after 48 hours, and the sutures were routinely removed on the seventh postoperative day from the preauricular area and on the 10<sup>th</sup> day from the temporal region.

Postoperatively, both patients were administered antibiotics for 1 week and started on a soft diet. They were encouraged to return to a normal diet as early as 1-2 weeks after their operation.

Patients began mouth opening exercises 8-48 hours after their operations.

Physiotherapy of the jaw was started from the day after surgery and consisted of daily active and passive range-of-motion activities. Subsequently, the patients continued daily physical therapy with the wooden tongue blade regularly at home.

**Follow up:** The patients were both kept on regular follow-up at weekly intervals during the first 6 months after surgery.

Both patients displayed uneventful healing with no complications and excellent postoperative results (Fig. 4).

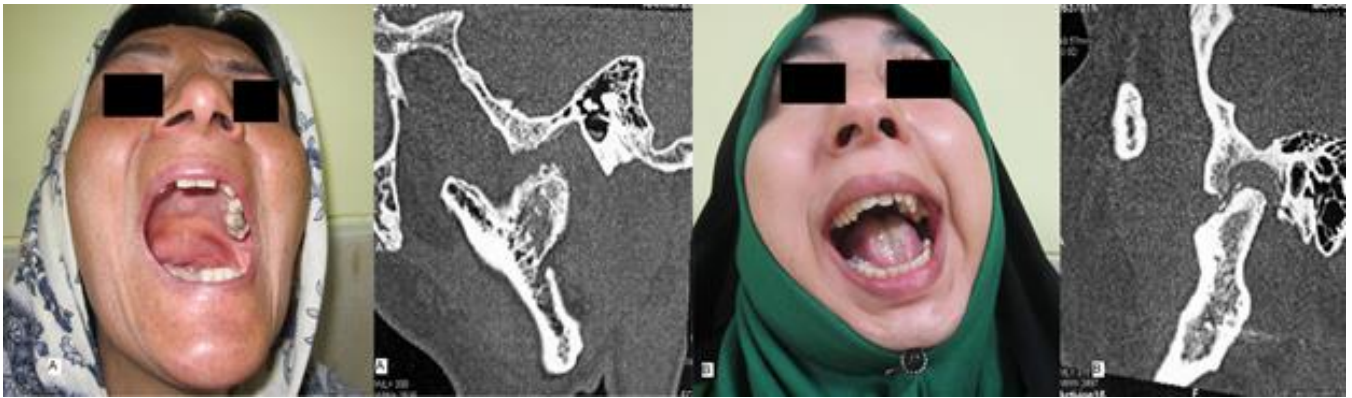
They both had full function in their facial nerves and no TMJ-related pain. Neither patient experienced any interference with eating.

Function and opening of mouth were very quick and without problems.

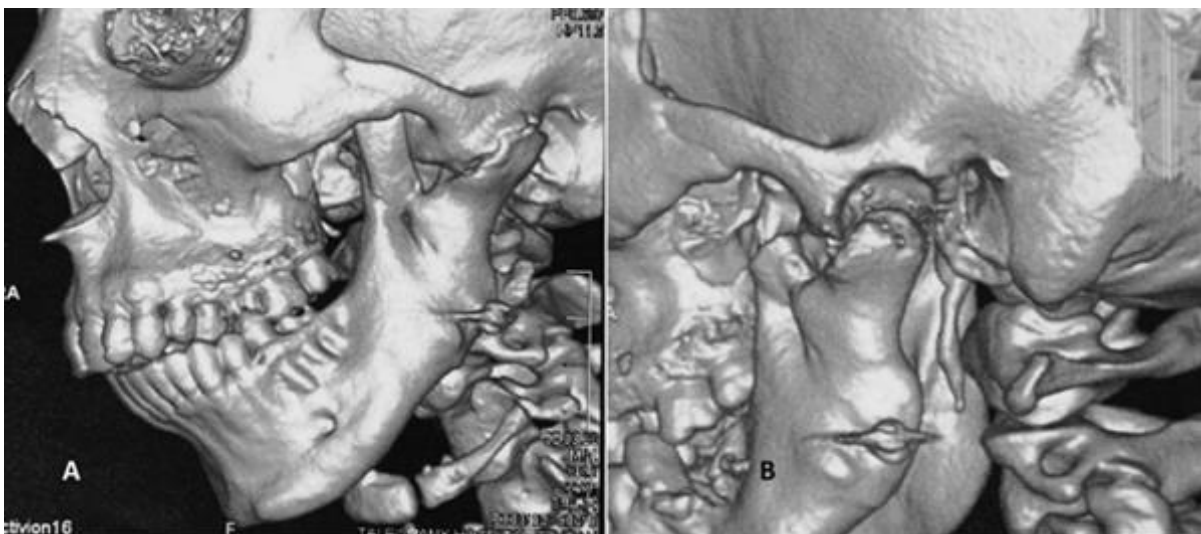### Ethical considerations

This the study was conducted in accordance with the Declaration of Helsinki. The written informed consent was obtained from patients included in this study. All data of patients were kept confidential.





**Figure-4.** A: Six month postoperative frontal view photograph and lateral view CT scan from the left TMJ of the first case. The patient could open her mouth 40 mm. B: Six month postoperative frontal view photograph and lateral view CT scan from the left TMJ of the second case. The patient could open her mouth 35 mm.



**Figure-5.** Lateral view 3D CT scan. A: before and B: after surgical operation of the second case, with coronoidectomy. As you see the ramus height has not been too short.

## Discussion

Several methods are used for the treatment of TMJ ankylosis. In 1854, whilst used the first condylectomy technique. In 1934, Risdone performed the first interpositional gap arthroplasty using interpositional materials. Alone, gap arthroplasty refers to those operations in which a space is created at least 15 mm (1, 2) or 1.5-2 cm (8, 9) with no material put in the recreated joint space (9).

Today, because of its high recurrence rate of ankylosis, gap arthroplasty is not a good option for the treatment of TMJ ankylosis (8). Although in interpositional gap arthroplasty a joint space is recreated, it is always less than one centimeter to avoid excessive shortening of the ramus length, and an autogenous or alloplastic material is utilized in the gap (5).

One of the advantages of interpositional gap arthroplasty is the decreased incidence of relapse (10). Many materials are used for insertion at the recreated gap after a condylectomy (8), including alloplastic materials (acrylic, proplast-teflon,

silastic) and autogenous tissues such as temporalis muscle flap, dermis, costochondral graft, cartilage, and buccal fat pad (8).

The temporalis muscle flap is the most common interpositional material used because of minimal cosmetic and functional donor site morbidity and because no further surgical sites are required because of its location near the TMJ (8, 17). However, to the best of the authors' knowledge, no material has been recommended as ideal for this purpose in recent investigations (18).

Another treatment plan is reconstruction of the joint using an autogenous or alloplastic graft after condylectomy (12). Gillies suggested that costochondral graft (CCG) as an autogenous graft can be useful for condyle reconstruction of the mandibular ramus after releasing the ankylotic region (3).

Studies have revealed that the gap arthroplasty technique with all its disadvantages is still more effective than resection and reconstruction of the mandibular condyle for

postoperative maximum mouth opening (19).

The main purposes of TMJ treatments in all surgical procedures are 1) to gain normal mouth opening, 2) to improve the patient's aesthetics, 3) to avoid inflammation and pain, and 4) to prevent reankylosis (18, 20, 21).

Treating TMJ ankylosis and secondary deformities in adult patients remains a great challenge for surgeons (3, 12). Although there are several techniques for the management of such patient, no single method has been uniformly reported as successful. Because there is much controversy regarding which technique is better, some surgeons follow the staged approach of treating TMJ ankylosis first and then deformities separately, whereas others prefer to release the ankylosis region and correct secondary deformities at the same time. Most of the time, a combination of several techniques should be used (12, 20).

In the modified technique proposed herein, the approach and use of the interpositional temporalis muscle are similar to the interpositional gap arthroplasty technique; however, differences include the minimal reduction of the ankylotic area and reshaping of the condylar pattern.

In this modification, a gap of just 6-7 mm is created to release the ankylotic condyle. Therefore, the height of the mandibular ramus is maintained (Fig. 5). This concept is considered an advantage, because it makes a better situation for bone and orthognathic surgery and DO either in the future or simultaneously. Moreover, these conditions can prevent changes in the maxillary occlusal plane and in internal face structures due to unilateral mandibular growth.

Nevertheless, this method has some disadvantages, such as longer operating times and difficulty in designing the contour of the head of the ramus on the bone under surgical conditions. As with most surgical procedures, the outcomes of this method depend upon the patient's cooperation.

## Conclusions

- This technique minimizes the reduction of the vertical height of the ramus.
- Because the ramus height is preserved and the condylar area is reshaped, some procedures like DO or orthognathic surgery are much simpler than when other techniques are used on their own.
- With this technique, the shape of the condyle and the height of the ramus is preserved as much as possible.
- More cases are needed to prove the validity of this treatment method.

## Acknowledgments

The authors thanks to patients for participating in current study.

## Authors' Contribution

All authors pass the four criteria for authorship contribution based on the International Committee of Medical Journal Editors (ICMJE) recommendations.

## Conflict of Interests

The authors declared no potential conflict of interests with respect to the research, authorship, and/or publication of this article.

## Funding/Support

The authors received no financial funding or support for the research.

## References

1. Jain G, Kumar S, Rana AS, Bansal V, Sharma P, Vikram A. Temporomandibular joint ankylosis: a review of 44 cases. *Oral and maxillofacial surgery*. 2008;12(2):61-6.
2. Vasconcelos BC, Porto GG, Bessa-Nogueira RV, Nascimento MM. Surgical treatment of temporomandibular joint ankylosis: follow-up of 15 cases and literature review. *Medicina oral, patologia oral y cirugia bucal*. 2009;14(1):E34-8.
3. Liu Y, Li J, Hu J, Zhu S, Luo E, Hsu Y. Autogenous coronoid process pedicled on temporal muscle grafts for reconstruction of the mandible condylar in patients with temporomandibular joint ankylosis. *Oral surgery, oral medicine, oral pathology, oral radiology, and endodontics*. 2010;109(2):203-10.
4. Karaca C, Barutcu A, Baytekin C, Yilmaz M, Menderes A, Tan O. Modifications of the inverted T-shaped silicone implant for treatment of temporomandibular joint ankylosis. *Journal of cranio-maxillo-facial surgery : official publication of the European Association for Cranio-Maxillo-Facial Surgery*. 2004;32(4):243-6.
5. Li ZB, Li Z, Shang ZJ, Zhao JH, Dong YJ. Potential role of disc repositioning in preventing postsurgical recurrence of traumatogenic temporomandibular joint ankylosis: a retrospective review of 17 consecutive cases. *International journal of oral and maxillofacial surgery*. 2006;35(3):219-23.
6. Pilmane M, Skagers A. Growth factors, genes, bone proteins and apoptosis in the temporomandibular joint (TMJ) of children with ankylosis and during disease recurrence. *Stomatologija*. 2011;13(3):96-101.
7. Kaur T, Krishnan G, Sharma A. Factors Influencing Treatment Plan and Post Operative Compliance in TMJ Ankylosis Patients: A Retrospective Analysis of Long Term Post Surgical Evaluation. *Journal of maxillofacial and oral surgery*. 2015;14(1):17-23.
8. Singh V, Dhingra R, Sharma B, Bhagol A, Kumar P. Retrospective analysis of use of buccal fat pad as an interpositional graft in temporomandibular joint ankylosis: preliminary study. *Journal of oral and maxillofacial surgery*. 2011;69(10):2530-6.
9. Elgazzar RF, Abdelhady AI, Saad KA, Elshaal MA, Hussain MM, Abdelal SE, et al. Treatment modalities of TMJ ankylosis: experience in Delta Nile, Egypt. *International journal of oral and maxillofacial surgery*. 2010;39(4):333-42.
10. Yavary MRT. Comparion of gap arthroplasty and interpositional gap arthroplasty on the temporomandibular joint ankylosis. *Acta Medica Iranica*. 2006;391-4.
11. Dayashankara Rao JK, Dar N, Sharma A, Sheorain AK, Malhotra V, Arya V. Evaluation of the Sternoclavicular Graft for the Reconstruction of Temporomandibular Joint After Gap Arthroplasty. *Annals of maxillofacial surgery*. 2017;7(2):194-201.
12. Zhu S, Li J, Luo E, Feng G, Ma Y, Hu J. Two-stage treatment protocol for management of temporomandibular joint ankylosis with secondary deformities in adults: our institution's experience.

- Journal of oral and maxillofacial surgery : official journal of the American Association of Oral and Maxillofacial Surgeons. 2011;69(12):e565-72.
13. Long X, Li X, Cheng Y, Yang X, Qin L, Qiao Y, et al. Preservation of disc for treatment of traumatic temporomandibular joint ankylosis. Journal of oral and maxillofacial surgery : official journal of the American Association of Oral and Maxillofacial Surgeons. 2005;63(7):897-902.
14. Shirani G, Arshad M, Mahmoudi X. A New Method of Treatment of Temporomandibular Joint Ankylosis with Osteodistraction Using the Sh-Device: A Case Report. Journal of dentistry (Tehran, Iran). 2018;15(1):63-8.
15. Gundlach KK. Ankylosis of the temporomandibular joint. Journal of cranio-maxillo-facial surgery : official publication of the European Association for Cranio-Maxillo-Facial Surgery. 2010;38(2):122-30.
16. August M, Troulis MJ, Kaban LB. Hypomobility and hypermobility disorders of the temporomandibular joint. Peterson's principles of oral and maxillofacial surgery London: BC Decker. 2004:1033-47.
17. Smith JA, Sandler NA, Ozaki WH, Braun TW. Subjective and objective assessment of the temporalis myofascial flap in previously operated temporomandibular joints. Journal of oral and maxillofacial surgery : official journal of the American Association of Oral and Maxillofacial Surgeons. 1999;57(9):1058-65; discussion 65-7.
18. Rajurkar SG, Makwana R, Ranadive P, Deshpande MD, Nikunj A, Jadhav D. Use of Temporalis Fascia Flap in the Treatment of Temporomandibular Joint Ankylosis: A Clinical Audit of 5 Years. Contemporary clinical dentistry. 2017;8(3):347-51.
19. Katsnelson A, Markiewicz MR, Keith DA, Dodson TB. Operative management of temporomandibular joint ankylosis: a systematic review and meta-analysis. Journal of Oral and Maxillofacial Surgery. 2012;70(3):531-6.
20. Sharma R, Manikandhan R, Sneha P, Parameswaran A, Kumar JN, Sailer HF. Neocondyle distraction osteogenesis in the management of temporomandibular joint ankylosis: Report of five cases with review of literature. Indian journal of dental research 2017;28(3): 269-74.
21. Braimah R, Taiwo A. Clinical experience in managing temporomandibular joint ankylosis: five-year appraisal in a Nigerian subpopulation. 2018;44(3):112-9.