



Diagnosing Hand and Wrist Tendon Injuries in Patients with Questionable Physical Findings: Let POCUS Show Its True Mettle

Reza Akhavan¹, Ehsan Bolvardi¹, Masoud Pezeshki-Rad¹ and Bita Abbasi^{1,*}

¹Faculty of Medicine, Mashhad University of Medical Sciences, Mashhad, Iran

*Corresponding author: Radiology Department, Imam Reza Hospital, Razi Sq., Mashhad, Iran. Tel/Fax: +98-5138525004, Email: abbasib@mums.ac.ir

Received 2018 February 25; Revised 2018 July 28; Accepted 2019 January 28.

Abstract

Background: The hand and wrist are functionally the most important parts of the body that are also very prone to traumatic injuries. Clinical examinations have inherent shortcomings in accurate diagnosis of tendon injuries. This makes diagnostic surgical exploration mandatory in the setting of questionable clinical findings. It is valuable to have an adjunctive diagnostic modality on hand to complement clinical findings and obviate the need for unnecessary surgery.

Objectives: The primary purpose of this article was to investigate the overall accuracy of point of care ultrasound performed by emergency physicians for the diagnosis of tendon lacerations.

Methods: One hundred and twelve patients with penetrating trauma to the volar aspect of hand or wrist and questionable clinical findings took part in this prospective study. All patients were candidates for exploratory surgery and underwent diagnostic ultrasonography to evaluate tendon rupture before surgery. Ultrasound results were compared with surgical evaluation results as the standard test.

Results: This research found a specificity of 99.4% and sensitivity of 100% for POCUS in the diagnosis of tendon rupture in traumas to the volar aspect of the hand and wrist.

Conclusions: The POCUS can be a reliable modality to evaluate tendon injuries in patients with suspicious clinical findings. Using this modality may obviate the need for a mere diagnostic surgical exploration.

Keywords: Tendon Lacerations, Ultrasound, Imaging Studies, Point-of-Care Ultrasound

1. Background

Hand and wrist are functionally the most important parts of the body that are also very prone to traumatic injuries (1), as they constitute about 30% of patients treated in emergency departments (2). Although clinical examination remains the first diagnostic test in cases of suspected tendon injury, it may be very tricky in evaluating partial thickness tears or non-cooperative patients (3). Clinical examinations have inherent shortcomings that make them inappropriate to rule out tendon injuries in all trauma patients. These limitations may come from lack of patient cooperation, or extent of tissue damage that makes tendon examination impossible. This may eventually lead the physician to opt for surgical exploration in order to detect tendon injuries; however, in many cases, tendons suspected to have lacerations are ultimately proved intact, and no therapeutic measures would be required. On the other hand, clinical examination may not be able to detect partial tendon injuries in many cases and surgical exploration remains to be the sole problem solver in such situa-

tions. Surgical exploration is warranted in cases of known tendon injury or other injuries, such as displaced fractures or foreign bodies, yet it is an aggressive, expensive, and time-consuming process that is not justified to be performed as a sole diagnostic modality in patients that will be eventually proved to have no tendon injuries. Accurate imaging studies that can determine the exact situation of a potentially torn tendon are very valuable and preclude the need for a more aggressive process (4). Point-of-care ultrasound (POCUS) is a new promising ultrasound technique that can be performed by emergency physicians in a bedside manner and reduce delay in diagnosis of many musculoskeletal pathologies, such as fractures, foreign bodies, effusion, synovitis, etc. (5-7). It is an easy, portable, repeatable, and non-ionizing method.

2. Objectives

Considering the paucity of studies on the economic and health/welfare benefits of POCUS in diagnosing ten-

don lacerations, especially in Iran, the researchers decided to evaluate the accuracy of this technique in the diagnosis of tendon injuries of hand and wrist in trauma patients with questionable clinical examination.

3. Methods

3.1. Settings

This study was conducted in a level 1 academic trauma center. Patients with penetrating trauma to volar aspects of hand and wrist during a 20-month period (March 2015 to October 2016) were evaluated as possible candidates of being enrolled in the study. Two emergency medicine attending physicians, three POCUS-trained emergency medicine residents, and two radiology attending physicians participated in this study. The emergency medicine residents were trained by attending radiologists in a three-week course and each performed at least 20 wrist tendon ultrasound examinations under their supervision.

3.2. Study Design and Participants

This prospective study was designed to evaluate the accuracy of POCUS for detecting tendon injuries in a carefully selected group of patients. The emergency physicians, who cooperated in the study were two faculty attending members with at least a five-year experience in a level one trauma center. Over a course of 20 months, in the shifts that the POCUS-trained emergency residents were available, the patients, who referred to the emergency department for penetrating trauma to the volar aspect of hand and wrist, were comprehensively examined by an attending emergency physician. The patients were categorized to three groups based on physical examination: (1) patients, who needed surgery for an obvious tendon injury, foreign body or neurovascular compromise, (2) patients, who needed an exploratory surgery because of possible tendon injury in physical examination (e.g. decreased and/or painful range of motion) or those, who needed exploratory surgery because of indeterminate results on physical examination (e.g. patients with decreased level of consciousness, or those, who did not cooperate in physical examination), and (3) patients with completely normal physical examination (not painful nor decreased range of motion). Patients in the second group were considered as clinically questionable for tendon injuries and were regarded as eligible candidates for being enrolled in the study, while patients in the first group were directly admitted to the orthopedic ward and those in the third group were discharged from the ED after appropriate wound management. An orthopedic resident was available all the time

in the ED and visited all patients with questionable findings. The inclusion criteria included hemodynamically stable patients over 18 years of age with penetrating injury to the volar aspect of hand or wrist, lack of any previous history of tendon injury at the same site, and giving a written consent to perform a bedside ultrasound examination before the definite diagnostic modality. The process was fully described to the patients or their next of kin, and written consent was obtained.

Exclusion criteria were as follows: (1) Age of younger than 18 years old, (2) hemodynamic instability, (3) lack of informed consent, (4) simultaneous severe damage to other organs, (5) severe tissue trauma or active bleeding, preventing the ultrasound evaluation of the affected extremity, (6) simultaneous joint damage, (7) traumatic amputation, (8) burns, (9) crush injury (10) previous injury at the same anatomic location, and (11) fingertip injuries.

3.3. Test Methods

Bedside ultra-sonographic examinations were performed by one of the three cooperating emergency medicine residents. They were asked to record the results as intact tendon or injured tendon. All sonographic assessments were performed according to the European Society of Musculoskeletal (ESSR) guidelines (8), using 12 MHz Sonosite™ surface probe. The superficial location of the hand and wrist tendons justified the use of a high-frequency (9 - 17 MHz) linear probe and a thick layer of coupling gel. The patients were asked to actively flex each interphalangeal and metacarpophalangeal joint, in order to better differentiate the tendons from adjacent structures, and also to distinguish superficial and deep flexor tendons. The evaluation of all tendons in the field of injury and the comparison with the opposite side were carefully performed. Tendons were traced from fingers to the wrist in both axial and longitudinal planes, in both resting and active flexion. The presence or absence of tendon injuries were recorded (Figure 1). To minimize bias, the ultrasound results were not reported to the patients.

Surgical exploration was performed by an orthopedic surgeon, who was not aware of the POCUS results. The surgical results were later extracted and recorded as the reference standards.

3.4. Data Analysis

The patients were classified, according to the ultrasound results to two groups (tendon injury and no tendon injury). The results of surgical exploration distributed the patients to two groups (tear/no tear).

For describing the data, tables and statistical parameters, such as mean and standard deviation, were used. To

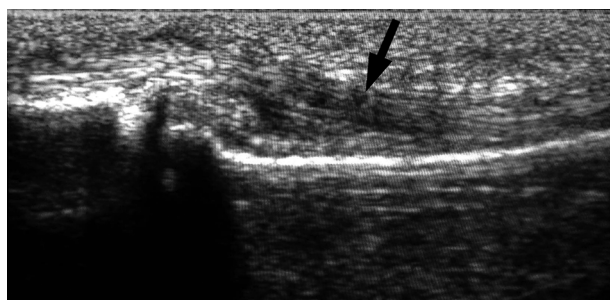

Figure 1. Longitudinal ultrasound image of a flexor tendon reveals an area of focal decrease in tendon echogenicity (arrow) that suggests partial tear

analyze the data, *t*-student test was performed and Kappa coefficient was measured, using SPSS V. 20 and Statistica V. 10. P values of less than 5% were considered statistically significant.

3.5. Ethical Consideration

The informed consents were obtained from hospital authorities and participants. The patients were ensured about the confidentiality of the obtained information.

4. Results

From 306 patients, who visited the emergency department during the study, 112 patients with questionable physical examination following penetrating trauma to hand or wrist, underwent surgical exploration (165 patients referred at times when no POCUS-trained residents were available and so were not enrolled in the study, 29 patients did not meet the inclusion criteria) (Figure 2). The demographic data is provided in Table 1. While performing the POCUS, all tendons that were located in the area of penetrating injury were evaluated and the results were recorded separately for each tendon, hence the researchers evaluated a sum of 214 separate tendons.

Table 1. Demographic and Clinical Characteristics

Subject characteristics	Percentage
Median age, y	26
Male/female	90.18/9.82
Right handed/left handed	93.03/6.97
Bone fracture	17.0
Context of injury	
Street fight	61.6
Work injury	25.0
Home	13.4

Based on surgical wound exploration, 48 tendons were partially or completely torn. Among these, ultrasound was able to accurately detect all the injured tendons. The cross-tabulation data of ultrasound and surgical exploration results are summarized in Table 2. The sensitivity of ultrasound in diagnosing tendon lacerations was 100% (92.6 to 100, 95%CI) and the specificity was 99.40% (96.69 to 99.98, 95%CI).

5. Discussion

Bedside ultrasound is a quick, inexpensive, and non-invasive tool, which can be of much use at the emergency department. Although most emergency physicians are familiar with the clinical applications of point of care ultrasound (POCUS) in situations like abdominal aortic aneurysm, hydronephrosis, deep venous thrombosis, central venous access, and pneumothorax (9), most of them forget about its invaluable applications in musculoskeletal emergencies. While evaluating musculoskeletal trauma patients, POCUS can be an easily performed adjunct for clinical examinations in order to assess the extent of injury. In addition, POCUS could be easily applied for patients, who do not cooperate while performing physical examinations and help the experts evaluate tendon injuries in different situations (10). In the current study, ultrasound enabled the researchers to identify all 48 cases of flexor tendon injuries of the wrist and hand. The sensitivity and specificity of ultrasound were 100% and 99.4% for flexor tendon injuries, respectively.

The researchers assumed that the case of false positive result has been due to anisotropy artifact. When tendons are evaluated longitudinally, ultrasound is perpendicular to tendon fibers. This makes the fibers become hyperechoic (white) with a lamellar pattern. If ultrasound beam hits the fibers in an oblique angle, the fibers become hypoechoic and anisotropy artifact ensues. This artificially hypoechoic pattern can be falsely interpreted as tendon tear. To avoid this error, tendons must be evaluated at different angles (11).

The researchers suggest that POCUS must be used as an adjunct to physical examination for the pre-operative assessment of flexor tendon lacerations. It seems to be able to determine the status of healthy and ruptured tendons more accurately and can also help the surgeons determine the surgical and incision site, particularly in cases where the proximal ruptured tendon is not palpable.

5.1. Limitations

In the present study, three emergency residents that had already been trained for tendon ultrasound evaluation

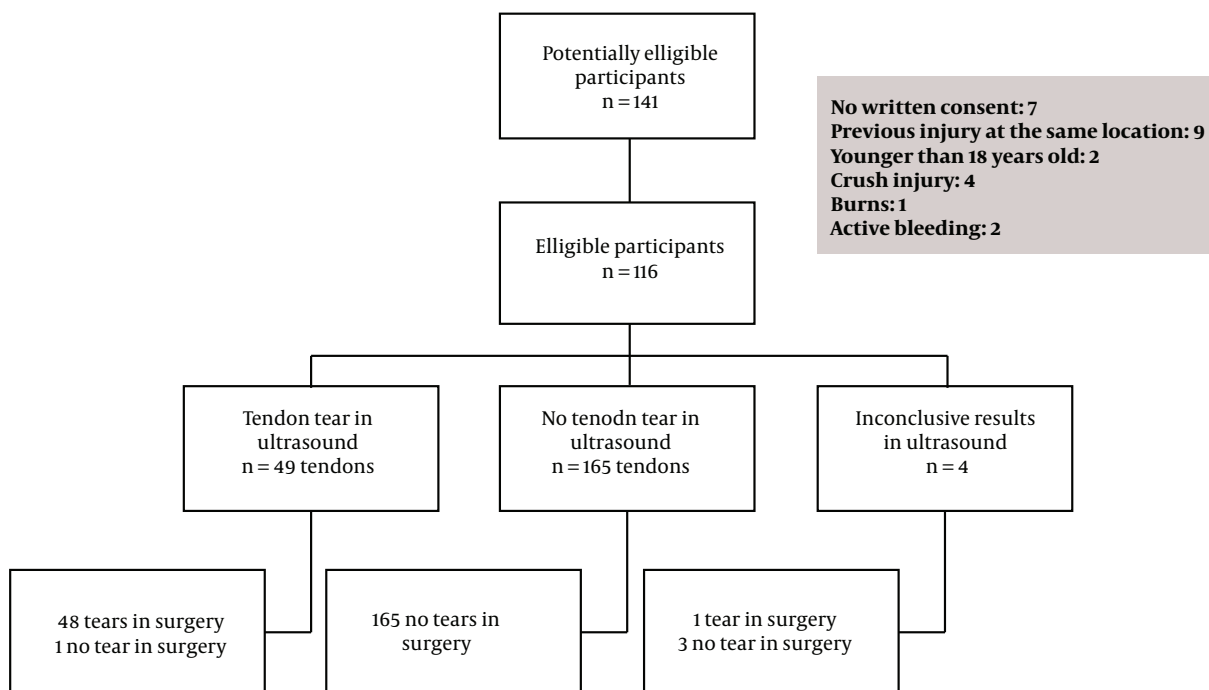


Figure 2. Flow of participants

Table 2. POCUS in Tendon Laceration

Surgical Exploration	POCUS		Sensitivity	Specificity
	No Injury	Injury		
No injury	165	1	(48/48) 100% (92.6-100 95%CI)	(165/166) 99.4% (96.69- 99.98 95%CI)
Injury	0	48		

performed the sonographic examinations. As a result, not all patients referred to the emergency department with hand and wrist injury could be enrolled in the study. Another problem in using bedside ultrasound by emergency physician for evaluating tendon injuries is that emergency physicians need to gain suitable amounts of experience before correctly and reliably performing and interpreting an ultrasound examination. The current results are only applicable to a restricted situation, in which the emergency physician is well aware of the tendon ultrasonographic images and potential pitfalls in sonographic diagnosis of tendon lacerations.

This study only included patients with a questionable clinical examination that were candidates for surgical exploration to evaluate for tendon injury. The results of the study are not applicable to those with completely normal physical examination (no painful or decreased range of motion), or those with obvious tendon tears. This situation is what happens in common clinical practice, as this group

of patients would be discharged from the ED without any further evaluation.

Some factors like air or foreign body in the tissue may make ultrasound less reliable and more difficult to perform. In the current study, these patients were not included in the final data analysis.

5.2. Conclusions

The researchers conclude that POCUS can be reliable for the evaluation of tendon injuries in patients with questionable clinical findings. This modality obviates the need for a mere diagnostic surgical exploration and decreases morbidity in patients and disease burden on health care systems.

Acknowledgments

The researchers are grateful of all patients for their kind participation. The statistical advices of Dr. Meshkat

are appreciated.

Footnotes

Conflict of Interests: The authors declare no conflict of interests.

Ethical Approval: The manuscript was approved under ethic code number #910322 by chancellor of research, Mashhad University of Medical Sciences.

Financial Disclosure: The authors have no financial disclosure.

Funding/Support: This research was supported by a grant provided by the chancellor for research of Mashhad University of Medical Sciences, Mashhad, Iran.

References

- Oguz AB, Polat O, Eneyli MG, Gulunay B, Eksioglu M, Gurler S. The efficiency of bedside ultrasonography in patients with wrist injury and comparison with other radiological imaging methods: A prospective study. *Am J Emerg Med.* 2017;**35**(6):855-9. doi: [10.1016/j.ajem.2017.01.043](https://doi.org/10.1016/j.ajem.2017.01.043). [PubMed: 28139307].
- Schoffl V, Heid A, Kupper T. Tendon injuries of the hand. *World J Orthop.* 2012;**3**(6):62-9. doi: [10.5312/wjo.v3.i6.62](https://doi.org/10.5312/wjo.v3.i6.62). [PubMed: 22720265]. [PubMed Central: [PMC3377907](https://pubmed.ncbi.nlm.nih.gov/PMC3377907/)].
- Soubeyrand M, Biau D, Jomaah N, Pradel C, Dumontier C, Nourissat G. Penetrating volar injuries of the hand: Diagnostic accuracy of US in depicting soft-tissue lesions. *Radiology.* 2008;**249**(1):228-35. doi: [10.1148/radiol.2491071679](https://doi.org/10.1148/radiol.2491071679). [PubMed: 18796679].
- Lee DH, Robbin ML, Galliot R, Graveman VA. Ultrasound evaluation of flexor tendon lacerations. *J Hand Surg Am.* 2000;**25**(2):236-41. doi: [10.1053/jhsu.2000.jhsu25a0236](https://doi.org/10.1053/jhsu.2000.jhsu25a0236). [PubMed: 10722814].
- Chartier LB, Bosco L, Lapointe-Shaw L, Chenkin J. Use of point-of-care ultrasound in long bone fractures: A systematic review and meta-analysis. *CJEM.* 2017;**19**(2):131-42. doi: [10.1017/cem.2016.397](https://doi.org/10.1017/cem.2016.397). [PubMed: 27916021].
- Abbasi B, Pezeshki-Rad M, Akhavan R, Sahebari M. Association between clinical and sonographic synovitis in patients with painful knee osteoarthritis. *Int J Rheum Dis.* 2017;**20**(5):561-6. doi: [10.1111/1756-185X.12834](https://doi.org/10.1111/1756-185X.12834). [PubMed: 26915050].
- Bolvardi E, Pezeshki Rad M, Abbasi B, Akhavan R. Is bedside ultrasound a reliable method for detecting soft tissue foreign bodies in upper extremity penetrating trauma patients? *Razavi Int J Med.* 2014;**2**(4). doi: [10.5812/rijm.22070](https://doi.org/10.5812/rijm.22070).
- Beggs I, Bianchi S, Bueno A, Cohen M, Court-Payen M, Grainger A, et al. *Musculoskeletal Ultrasound Technical Guidelines III. Wrist.* European Society of MusculoSkeletal Radiology; 2010.
- Nagaraj G, Chu M, Dinh M. Emergency clinician performed ultrasound: Availability, uses and credentialing in Australian emergency departments. *Emerg Med Australas.* 2010;**22**(4):296-300. doi: [10.1111/j.1742-6723.2010.01306.x](https://doi.org/10.1111/j.1742-6723.2010.01306.x). [PubMed: 20636359].
- Chen KC, Lin AC, Chong CF, Wang TL. An overview of point-of-care ultrasound for soft tissue and musculoskeletal applications in the emergency department. *J Intensive Care.* 2016;**4**:55. doi: [10.1186/s40560-016-0173-0](https://doi.org/10.1186/s40560-016-0173-0). [PubMed: 27529031]. [PubMed Central: [PMC4983782](https://pubmed.ncbi.nlm.nih.gov/PMC4983782/)].
- Westerheide E, Failla JM, van Holsbeeck M, Ceulemans R. Ultrasound visualization of central slip injuries of the finger extensor mechanism. *J Hand Surg Am.* 2003;**28**(6):1009-13. doi: [10.1016/S0363-5023\(03\)00427-1](https://doi.org/10.1016/S0363-5023(03)00427-1). [PubMed: 14642518].