



# Matricaria Chamomilla Extract Improves Diabetic Wound Healing in Rat Models

Parisa Nematollahi<sup>1</sup>, Nasrin Mohammadi Aref<sup>2</sup>, Farzaneh Zahmatkesh Meimandi<sup>1</sup>, Seyede Laya Rozei<sup>2</sup>, Hamidreza Zareé<sup>1</sup>, Seyyed Mohammad Javad Mirlohi<sup>2</sup>, Shima Rafiee<sup>1</sup>, Maryam Mohsenikia<sup>3</sup>, Ali Soleymani<sup>4</sup>, Soheil Ashkani-Esfahani<sup>1,\*</sup>, Alireza Ebrahimi<sup>1</sup> and Ali Noorafshan<sup>5</sup>

<sup>1</sup>Student Research Committee, Shiraz University of Medical Sciences, Shiraz, Iran

<sup>2</sup>Student Research Committee, Tehran Medical Sciences Branch, Islamic Azad University, Iran

<sup>3</sup>Young Researchers and Elite Club, Tehran Medical Branch, Islamic Azad University, Tehran, Iran

<sup>4</sup>Dezful University of Medical Sciences, Dezful, Iran

<sup>5</sup>Histomorphometry and Stereology Research Center, Shiraz University of Medical Sciences, Shiraz, Iran

\*Corresponding author: Student Research Committee, Shiraz University of Medical Sciences, Karimkhan Zand St., Shiraz, Iran. Email: soashkani@gmail.com

Received 2017 May 30; Revised 2018 September 26; Accepted 2018 October 14.

## Abstract

**Background:** Diabetes mellitus (DM) has a broad spectrum of complications and comorbidities. Delayed wound healing is a major reason for infections and further life-threatening complications; the process of vascularization and tissue regeneration as well as anti-inflammatory and anti-oxidant reactions of the body are impaired in DM. Matricaria Chamomilla (MC) is a herbal medicine which has antimicrobial, antioxidant and wound healing potentials.

**Objectives:** In this study, these potentials are evaluated on full thickness diabetic excisional skin wounds by using stereological methods.

**Methods:** In this experimental study, 48 male Wistar rats with streptozotocin (STZ)-induced diabetes (50 mg/kg intraperitoneally) were divided into 4 groups (n = 12) randomly: MC 5% gel treated, MC 10% gel treated, gel-base treated group, and the control group receiving no treatment. After creating 1 cm<sup>2</sup> wounds, rats were treated every 24 hours for 15 days. Volume densities of collagens, wound closure rate, volume density, length density, and mean diameter of vessels, and fibroblast proliferation, were examined and analyzed. P ≤ 0.05 was mentioned as statistically significant.

**Results:** MC gels receiving groups showed hastened wound area reduction in contrast with gel-base and control groups (P < 0.05). Numerical density of fibroblasts, mean diameter and length densities of the vessels in MC groups were significantly higher than the control and the base groups (P < 0.05).

**Conclusions:** It is demonstrated that MC has the ability to improve wound healing by enhancing fibroblast proliferation and revascularization in diabetic skin injuries and has the potential to be considered as an alternative treatment.

**Keywords:** Diabetes Mellitus, Wound, Matricaria Chamomilla, Stereology, Rat

## 1. Background

Diabetes mellitus (DM), its treatments and complications, are of the major concerns of today's medicine and medical research. Among the complications and dysfunctions caused by DM, impaired healing of skin injuries and wounds are of great importance (1-3). Wound healing is a biochemical process which leads to tissue regeneration and epithelization via activation and migration of fibroblasts, collagen and vessel production, and reformation of the injured tissue layers; these steps occur along with inflammatory and oxidative responses of the injured tissue (1, 3-7). All these steps and responses are significantly disrupted in DM (8); thus, skin wounds in diabetic individu-

als may cause certain problems such as limb amputation, organ malfunctions, cosmetic impairment, sepsis and infection, and even death (9, 10).

Beside the modern treatments of the diabetic wounds, traditional and herbal medicines are suggested by recent investigations because of their fewer reported side effects as well as diverse therapeutic potential (9, 10). Moreover, in many cultures, traditional therapies are accepted even more than the modern biochemical agents (11, 12). Matricaria Chamomilla (MC) is a herbal medicine, from the Asteraceae/Compositae family, with different substances which are effective on the parameters involved in wound healing such as inflammation, infection, ulceration, and

pain (13-20).

## 2. Objectives

The objective of this study is to determine the healing effect of MC on excisional skin wounds in diabetic rats by using stereological methods.

## 3. Methods

### 3.1. Extract and Gel Preparation

MC plant was provided from the Medipress™ Herbarium of Shiraz University of Medical Sciences, Shiraz, Iran (Code: 3103). All plant organs were used as the herbal material for making the extract. We dried the material at room temperature for 6-8 days and then it was ground into powder. Thereafter, the powder was extracted with a mixture of ethanol: water (1:1, v/v) for 72 hours. The obtained product was then filtered and then evaporated to make hydroalcoholic extract (yield: 23.35%). To ease the application of the medicine, we provided two concentrations of 5% and 10% MC gels by dissolving 5 cc (MC 5%) and 10 cc (MC 10%) of the herbal extract in 2 cc distilled water, respectively, and then we transferred the solution into carboxy-methylcellulose with 2% concentration (CMC; 2g CMC dissolved in 98 cc distilled water). The gel-base itself was also supplied by producing 2% CMC gel but without the MC component. The dosage of MC was chosen according to a pilot study on different doses of the extract including 2%, 5%, 10%, and 20%.

### 3.2. Animals and Creating the Wounds

In an experimental study, 48 male Wistar rats (200 ± 20 g; 2 to 3 months old) kept in standard condition, regular cages, sufficient food and water ad libitum, were randomly divided into 4 identical groups (n = 12) including: control group receiving no treatment, gel-base group, MC 5% (E1) and MC 10% (E2) treated groups. By administration of 50 mg per kg body weight streptozotocin (STZ; Sigma Aldrich™, Germany) intraperitoneally (IP), diabetes was induced on day 0, according to previously used method (21). The blood sugar (BS) was determined by using a glucometer (GM101, Bionime Rightest™, Dali city, Taiwan) and the BS higher than 250 mg/dl was considered as a diabetic rat. On day 0, one 1 cm<sup>2</sup> circular excisional full-thickness wound was created on the posterior surface of each rat's neck under general anesthesia induced with ether inhalation. The last day of the study was set according to the prior pilot study (day 15 here). The animals were euthanized after 15 days by inhaling a high dose of ether and full-thickness skin samples (1 × 1 cm<sup>2</sup>) were obtained from the epithelialized wound site. The samples were fixed in buffered

formaldehyde (pH = 7.2; Merk™, Germany) for stereological analyses.

The protocol of the study and the animal treatment guidelines were approved by the Medical Ethics Committee of Shiraz University of Medical Sciences, Shiraz, Iran.

### 3.3. Stereological Study

Every three days, a digital photograph was captured from the wound surface with a digital camera to estimate the wound closure rate. A ruler was set beside the wound site in each photograph for calibration of the magnification on the computer monitor. The closure rate was estimated by using the "point grid" method (9), using the following formula:

$$\text{Wound closure rate (\%)} = \frac{\text{Area at visit 1} - \text{Area at each visit}}{\text{Area at visit 1}} \times 100$$

A full-thickness circular sample with 1 cm diameter was removed from the wound site. Nine random pieces of 1 mm<sup>2</sup> from each skin sample were obtained by using a systematic random sampling method, and were embedded in a paraffin block. Isotropic uniformly random sections of the cylindrical blocks with thicknesses of 5 and 15 μm were prepared and were stained with hematoxylin and eosin (H & E). Volume densities of hair follicles, collagen bundles, and vessels, were determined by using "point counting" method described by a previous study performed in our center (21). The population of fibroblasts, mean diameter and length density of the vessels, were also measured (21).

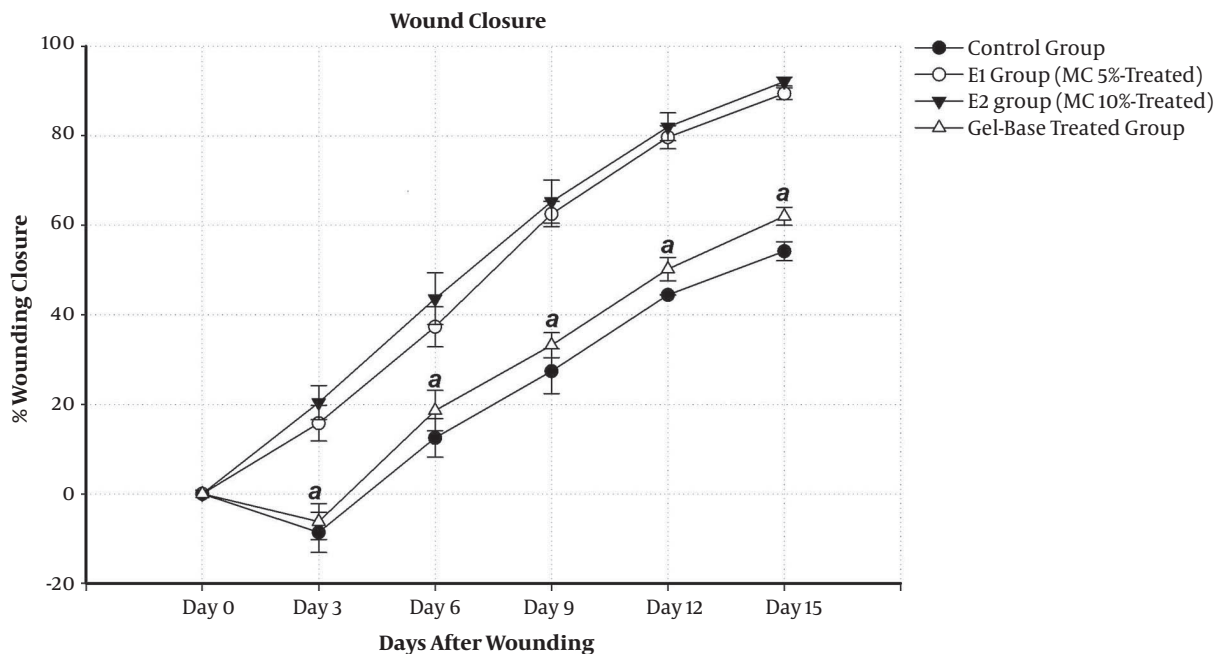
### 3.4. Statistical Analysis of the Data

Data were exhibited as mean ± standard deviation (mean ± SD). The SPSS statistical software (IBM™, version 19.0) was used to carry out the comparisons between the study groups. The analyses were done by using Kruskal Wallis plus Mann-Whitney U tests. Furthermore, P-value equal or lower than 0.05 was considered as statistically considerable.

## 4. Results

The mean initial wound area in all four groups was 103.31 ± 4.76 mm<sup>2</sup> with no significant contrast among the groups. Wound closure rates of E1 (5.96%/day) and E2 (6.14%/day) groups were noticeably higher than the control group (3.61%/day), P = 0.014 and P = 0.011, respectively, and gel-base treated group (4.13%/day), P = 0.027 and P = 0.019, respectively (Figure 1)

Fibroblasts' numerical density (Nv) revealing the population of the fibroblasts in the dermis of MC-treated groups were significantly higher in contrast with the control and gel-base groups (P < 0.05). As it is shown in Table 1,



**Figure 1.** The effect of MC on the wound closure rate in rats of the control group, gel base treated, MC 5% and MC 10% gels treated groups. Each point exhibits mean  $\pm$  SD of the twelve wounds. The "a" letter demonstrates considerable difference for the MC 5% and 10% -treated rats compared to the control group and the base group ( $P < 0.05$ ).

numerical density of fibroblasts in MC-treated groups, E1 and E2, were reported to be by 99% ( $P = 0.001$ ) and 106% ( $P < 0.001$ ) higher than the control group and by 84% ( $P = 0.003$ ) and 90% ( $P = 0.001$ ) higher than the gel-base treated group, respectively. Length densities of vessels in the dermis in both E1 and E2 groups were significantly higher in comparison to gel-base group ( $P = 0.004$  and  $P = 0.009$ , respectively) and the control group ( $P = 0.009$  and  $P = 0.012$ , respectively). Mean diameter of the vessels in E1 and E2 groups were also higher in comparison to gel-base group ( $P = 0.003$  and  $P = 0.005$ , respectively) and the control group ( $P = 0.001$  and  $P = 0.002$ , respectively).

However, the volume densities of the vessels and collagens in the dermis of MC-treated rats depicted no considerable differences with the gel-base treated rats and the controls (Table 1).

## 5. Discussion

DM is one of the disorders that affect the normal wound healing process by impairing the function of fibroblasts, growth and biochemical factors, remodeling processes, and many other parameters which are involved in tissue regeneration (22, 23). Thus, finding therapeutic agents which have the ability of improving the healing process by either improving the regeneration process through

fibroblast stimulation, collagen bundle synthesis and vascularization, or resorting the biochemical functions, transmissions, inflammatory, and oxidative responses, has always been a concern in medical researches.

Earlier experiments support the idea that specific herbal medicines are promising agents for wound healing based on their effective potentials such as anti-inflammatory and anti-oxidative activities, anti-microbial, and growth stimulatory impacts, as well as absence of unwanted side effects and availability (24). Results of previous studies showed that MC contains chamazulene, alpha bisabolol, bisabolol oxides, spiroethers, and flavenoids which have anti-inflammatory, antibacterial, and antifungal properties (11). Previous evaluations of wound healing effects of chamomile on ulcers of non-diabetic rats exhibited noticeable efficacy compared with topical corticosteroids (25). In a study conducted by Nayak et al. the effects of oral administration of chamomile flower extract in drinking water was evaluated. They noted that chamomile reduced wound size and inflammation, and also increased re-epithelialization, number of fibroblasts and collagen turnover (26). In addition, Jarrahi showed that topical administration of chamomile accelerated the healing process of burn wounds in rats (13). Duarte et al. revealed that chamomile stimulated re-epithelialization, fibroblast function, and the formation of collagen fibers after 10 days

**Table 1.** The Fibroblasts' Numerical Density ( $\times 10^3$  Per  $\text{mm}^3$ ), Volume Density of Vessels ( $V_{\text{vessel/dermis}}\%$ ), Volume Density of Collagen Bundles ( $V_{\text{collagen/dermis}}\%$ ), Mean Diameter ( $\mu\text{m}$ ) and Length Density ( $\text{mm}/\text{mm}^3$ ) of Vessels in the Dermis of the MC 5% (E1) and 10% (E2) Gels Treated, Gel-Base Treated, and Control Rats Which Had No Treatment

Groups	Fibroblasts	Collagen	Vessels		
	Numerical Density	Volume Density, %	Volume Density, %	Length Density	Mean Diameter
Control	184.52 (32.65)	47 (5)	1.02 (0.57)	25.46 (3.12)	10.63 (1.17)
E1	368.62 (47.77) <sup>a</sup>	52 (19)	1.11 (1.01)	40.29 (16.96) <sup>a</sup>	27.14 (6.85) <sup>a</sup>
E2	380.45 (18.51) <sup>a</sup>	51 (15)	1.40 (2.07)	31.66 (11.06) <sup>a</sup>	20.66 (8.26) <sup>a</sup>
Gel-base	200.22 (50.20)	49 (7)	1.21 (0.6)	17.16 (7.26)	11.25 (2.05)

<sup>a</sup>  $P < 0.05$ , vs. control group and/or gel-base group.

of treatment (27). Rezaie et al. compared topical MC with zinc oxide on experimental skin wounds in rats and reported that topical MC at the dose of 10% has superior healing potentials compared to zinc oxide (12). The results of present study showed that MC has promising effects on diabetic skin wounds regarding stereological parameters including wound closure, fibroblast population, and revascularization.

As a limitation of this study, the induction of diabetes by STZ might not be effective and some rats would not develop diabetes after one injection. Thus, we had to replace them. Moreover, some would die due to various reasons such as dehydration after developing diabetes. These were replaced as well if the death had occurred in the first three days of the study.

### 5.1. Conclusions

Being able to be introduced as a main or alternative treatment for diabetic wounds, further studies, particularly clinical trials, are still required to determine the efficacy as well as possible adverse effects of MC. However, the findings of this stereological study revealed that MC has the ability to improve the wound healing process in diabetic rats by increasing the fibroblast numbers and vascularization of the damaged tissue.

### Acknowledgments

This project has been financially supported by Shiraz University of Medical Sciences, Shiraz, Iran (Project no. 92-01-21-6709). Authors wanted to appreciate Dr. M. Vahedi, Mr. Omid Koohi-Hosseinabadi and all the personnel of Stem Cell and Transgenic Technology Research Center, and Elham Nadimi for instructions in stereological and histomorphometrical studies.

### Footnotes

**Authors' Contribution:** Proposal, pre-experimental research, provision of materials, lab experiments, and

data gathering: Parisa Nematollahi, Nasrin Mohammadi Aref, Farzaneh Zahmatkesh Meimandi, Seyede Laya Rozei, Hamidreza Zareé, Seyyed Mohammad Javad Mirlohi, Shima Rafiee, Maryam Mohsenikia and Ali Soleymani. Data Analysis, writing the draft: Soheil Ashkani-Esfahani and Alireza Ebrahimi. Editing the draft, supervising the project, and journal club: Ali Noorafshan. All the authors reviewed the final draft of the paper and participated in revisions.

**Conflict of Interests:** It is not declared by the authors.

**Ethical Approval:** The protocol of the study and the animal treatment guidelines were approved by the Medical Ethics Committee of Shiraz University of Medical Sciences, Shiraz, Iran.

**Funding/Support:** This project has been financially supported by Shiraz University of Medical Sciences, Shiraz, Iran (Project no. 92-01-21-6709).

### References

- Farzaei MH, Abbasabadi Z, Shams-Ardekani MR, Abdollahi M, Rahimi R. A comprehensive review of plants and their active constituents with wound healing activity in traditional Iranian medicine. *Wounds*. 2014;**26**(7):197-206.
- Guo S, Dipietro LA. Factors affecting wound healing. *J Dent Res*. 2010;**89**(3):219-29. doi: [10.1177/0022034509359125](https://doi.org/10.1177/0022034509359125). [PubMed: [20139336](https://pubmed.ncbi.nlm.nih.gov/20139336/)]. [PubMed Central: [PMC2903966](https://pubmed.ncbi.nlm.nih.gov/PMC2903966/)].
- Galkowska H, Wojewodzka U, Olszewski WL. Chemokines, cytokines, and growth factors in keratinocytes and dermal endothelial cells in the margin of chronic diabetic foot ulcers. *Wound Repair Regen*. 2006;**14**(5):558-65. doi: [10.1111/j.1743-6109.2006.00155.x](https://doi.org/10.1111/j.1743-6109.2006.00155.x). [PubMed: [17014667](https://pubmed.ncbi.nlm.nih.gov/17014667/)].
- Falanga V. Wound healing and its impairment in the diabetic foot. *Lancet*. 2005;**366**(9498):1736-43. doi: [10.1016/S0140-6736\(05\)67700-8](https://doi.org/10.1016/S0140-6736(05)67700-8). [PubMed: [16291068](https://pubmed.ncbi.nlm.nih.gov/16291068/)].
- Saaristo A, Tammela T, Farkkila A, Karkkainen M, Suominen E, Yla-Herttua S, et al. Vascular endothelial growth factor-C accelerates diabetic wound healing. *Am J Pathol*. 2006;**169**(3):1080-7. doi: [10.2353/ajpath.2006.051251](https://doi.org/10.2353/ajpath.2006.051251). [PubMed: [16936280](https://pubmed.ncbi.nlm.nih.gov/16936280/)]. [PubMed Central: [PMC1698814](https://pubmed.ncbi.nlm.nih.gov/PMC1698814/)].
- Kalay Z, Cevher SC. Oxidant and antioxidant events during epidermal growth factor therapy to cutaneous wound healing in rats. *Int Wound J*. 2012;**9**(4):362-71. doi: [10.1111/j.1742-481X.2011.00895.x](https://doi.org/10.1111/j.1742-481X.2011.00895.x). [PubMed: [22129466](https://pubmed.ncbi.nlm.nih.gov/22129466/)].

7. Saddiqe Z, Naeem I, Maimoona A. A review of the antibacterial activity of *Hypericum perforatum* L. *J Ethnopharmacol*. 2010;**131**(3):51-21. doi: [10.1016/j.jep.2010.07.034](https://doi.org/10.1016/j.jep.2010.07.034). [PubMed: [20659547](https://pubmed.ncbi.nlm.nih.gov/20659547/)].
8. Bagheri M, Jahromi BM, Mirkhani H, Solhjoui Z, Noorafshan A, Zamani A, et al. Azelnidipine, a new calcium channel blocker, promotes skin wound healing in diabetic rats. *J Surg Res*. 2011;**169**(1):e101-7. doi: [10.1016/j.jss.2011.02.039](https://doi.org/10.1016/j.jss.2011.02.039).
9. Rhoads DD, Cox SB, Rees EJ, Sun Y, Wolcott RD. Clinical identification of bacteria in human chronic wound infections: Culturing vs. 16S ribosomal DNA sequencing. *BMC Infect Dis*. 2012;**12**:321. doi: [10.1186/1471-2334-12-321](https://doi.org/10.1186/1471-2334-12-321). [PubMed: [23176603](https://pubmed.ncbi.nlm.nih.gov/23176603/)]. [PubMed Central: [PMC3542000](https://pubmed.ncbi.nlm.nih.gov/PMC3542000/)].
10. Kumar B, Vijayakumar M, Govindarajan R, Pushpangadan P. Ethnopharmacological approaches to wound healing-exploring medicinal plants of India. *J Ethnopharmacol*. 2007;**114**(2):103-13. doi: [10.1016/j.jep.2007.08.010](https://doi.org/10.1016/j.jep.2007.08.010). [PubMed: [17884316](https://pubmed.ncbi.nlm.nih.gov/17884316/)].
11. Avallone R, Zanolli P, Puia G, Kleinschnitz M, Schreier P, Baraldi M. Pharmacological profile of apigenin, a flavonoid isolated from *Matricaria chamomilla*. *Biochem Pharmacol*. 2000;**59**(11):1387-94. [PubMed: [10751547](https://pubmed.ncbi.nlm.nih.gov/10751547/)].
12. Rezaie A, Mohajeri D, Zarkhah A, Nazeri M. Comparative assessment of *Matricaria chamomilla* and zinc oxide on healing of experimental skin wounds on rats. *Ann Biol Res*. 2012;**3**(1):550-60.
13. Jarrahi M. An experimental study of the effects of *Matricaria chamomilla* extract on cutaneous burn wound healing in albino rats. *Nat Prod Res*. 2008;**22**(5):422-7. doi: [10.1080/14786410701591713](https://doi.org/10.1080/14786410701591713). [PubMed: [18404562](https://pubmed.ncbi.nlm.nih.gov/18404562/)].
14. Szoke E, Maday E, Tyihak E, Kuzovkina IN, Lemberkovics E. New terpenoids in cultivated and wild chamomile (in vivo and in vitro). *J Chromatogr B Analyt Technol Biomed Life Sci*. 2004;**800**(1-2):231-8. [PubMed: [14698259](https://pubmed.ncbi.nlm.nih.gov/14698259/)].
15. Lyseng-Williamson KA, Perry CM. Micronised purified flavonoid fraction: A review of its use in chronic venous insufficiency, venous ulcers and haemorrhoids. *Drugs*. 2003;**63**(1):71-100. doi: [10.2165/00003495-200363010-00005](https://doi.org/10.2165/00003495-200363010-00005). [PubMed: [12487623](https://pubmed.ncbi.nlm.nih.gov/12487623/)].
16. Gardiner P. Complementary, holistic, and integrative medicine: Chamomile. *Pediatr Rev*. 2007;**28**(4):e16-8. [PubMed: [17400821](https://pubmed.ncbi.nlm.nih.gov/17400821/)].
17. Way TD, Kao MC, Lin JK. Apigenin induces apoptosis through proteasomal degradation of HER2/neu in HER2/neu-overexpressing breast cancer cells via the phosphatidylinositol 3-kinase/Akt-dependent pathway. *J Biol Chem*. 2004;**279**(6):4479-89. doi: [10.1074/jbc.M305529200](https://doi.org/10.1074/jbc.M305529200). [PubMed: [14602723](https://pubmed.ncbi.nlm.nih.gov/14602723/)].
18. Patel D, Shukla S, Gupta S. Apigenin and cancer chemoprevention: progress, potential and promise (review). *Int J Oncol*. 2007;**30**(1):233-45. [PubMed: [17143534](https://pubmed.ncbi.nlm.nih.gov/17143534/)].
19. Gates MA, Tworoger SS, Hecht JL, De Vivo I, Rosner B, Hankinson SE. A prospective study of dietary flavonoid intake and incidence of epithelial ovarian cancer. *Int J Cancer*. 2007;**121**(10):2225-32. doi: [10.1002/ijc.22790](https://doi.org/10.1002/ijc.22790). [PubMed: [17471564](https://pubmed.ncbi.nlm.nih.gov/17471564/)].
20. Shukla S, Mishra A, Fu P, MacLennan GT, Resnick MI, Gupta S. Up-regulation of insulin-like growth factor binding protein-3 by apigenin leads to growth inhibition and apoptosis of 22Rv1 xenograft in athymic nude mice. *FASEB J*. 2005;**19**(14):2042-4. doi: [10.1096/fj.05-3740fje](https://doi.org/10.1096/fj.05-3740fje). [PubMed: [16230333](https://pubmed.ncbi.nlm.nih.gov/16230333/)].
21. Ashkani-Esfahani S, Zarifi F, Asgari Q, Samadnejad AZ, Rafiee S, Noorafshan A. Taurine improves the wound healing process in cutaneous leishmaniasis in mice model, based on stereological parameters. *Adv Biomed Res*. 2014;**3**:204. doi: [10.4103/2277-9175.142314](https://doi.org/10.4103/2277-9175.142314). [PubMed: [25337534](https://pubmed.ncbi.nlm.nih.gov/25337534/)]. [PubMed Central: [PMC4202507](https://pubmed.ncbi.nlm.nih.gov/PMC4202507/)].
22. Ponrasu T, Subamekala MK, Ganeshkuma M, Suguna L. Role of *Annona squamosa* on antioxidants during wound healing in streptozotocin-nicotinamide induced diabetic rats. *J Pharm Phytochem*. 2013;**2**(4):77-84.
23. Goodson WH, Hung TK. Studies of wound healing in experimental diabetes mellitus. *J Surg Res*. 1977;**22**(3):221-7. [PubMed: [14280](https://pubmed.ncbi.nlm.nih.gov/14280/)].
24. Ponrasu T, Suguna L. Efficacy of *Annona squamosa* on wound healing in streptozotocin-induced diabetic rats. *Int Wound J*. 2012;**9**(6):613-23. doi: [10.1111/j.1742-481X.2011.00924.x](https://doi.org/10.1111/j.1742-481X.2011.00924.x). [PubMed: [22233431](https://pubmed.ncbi.nlm.nih.gov/22233431/)].
25. Martins MD, Marques MM, Bussadori SK, Martins MA, Pavesi VC, Mesquita-Ferrari RA, et al. Comparative analysis between *Chamomilla recutita* and corticosteroids on wound healing. An in vitro and in vivo study. *Phytother Res*. 2009;**23**(2):274-8. doi: [10.1002/ptr.2612](https://doi.org/10.1002/ptr.2612). [PubMed: [18803230](https://pubmed.ncbi.nlm.nih.gov/18803230/)].
26. Nayak BS, Raju SS, Rao AV. Wound healing activity of *Matricaria recutita* L. extract. *J Wound Care*. 2007;**16**(7):298-302. doi: [10.12968/jowc.2007.16.7.27061](https://doi.org/10.12968/jowc.2007.16.7.27061). [PubMed: [17708380](https://pubmed.ncbi.nlm.nih.gov/17708380/)].
27. Duarte CM, Quirino MR, Patrocinio MC, Anbinder AL. Effects of *Chamomilla recutita* (L.) on oral wound healing in rats. *Med Oral Patol Oral Cir Bucal*. 2011;**16**(6):e716-21. [PubMed: [2196867](https://pubmed.ncbi.nlm.nih.gov/2196867/)].