

Experience With Medialization Thyroplasty and Freeze-Dried Cadaveric Human Fascia Lata in Unilateral True Vocal Cord Paralysis

Farzad Izadi,¹ Hosein Rasoolpanah,² Mojtaba Maleki,³ Aslan Ahmadi,² Ehsan Shams Koushki,^{4,*}

Somaye Kazemipour,⁴ and Maryam Nikravesht⁵

¹Associate Professor of Otolaryngology and Head and Neck Surgery, ENT and Head and Neck Research Center and Department, Hazrate Rasoul Medical Center, Iran University of Medical Sciences, Tehran, Iran

²Assistant Professor of Otolaryngology and Head and Neck Surgery, ENT and Head and Neck Research Center and Department, Hazrate Rasoul Medical Center, Iran University of Medical Sciences, Tehran, Iran

³Assistant Professor of Otolaryngology and Head and Neck Surgery, Firouzgar Medical Center, Iran University of Medical Sciences, Tehran, Iran

⁴Otolaryngologist and Head and Neck Surgeon, Hazrate Rasoul Medical Center, Iran University of Medical Sciences, Tehran, Iran

⁵Department of Speech and Language Pathology, School of Rehabilitation Sciences, Iran University of Medical Sciences, Tehran, Iran

*Corresponding author: Ehsan Shams Koushki, Research center and Department of Otolaryngology and Head and Neck Surgery of Hazrate Rasoul Hospital, Niaeshstreet, Sattarkhan Avenue, Tehran, Iran. Tel: +98-9122185334, E-mail: ehchk@yahoo.com

Received 2016 August 17; Revised 2017 February 28; Accepted 2017 September 04.

Abstract

Background: Use of autologous fascia, harvested from the thigh fascia lata, has been shown to be effective in the treatment of unilateral vocal fold paralysis (UVFP). However, advantages of this material have been less examined in the clinical setting. The present study aimed to assess the beneficial effects of medialization thyroplasty type I with cadaveric fascia lata on the vocal function of patients with UVFP.

Methods: This prospective interventional case series was performed on 10 patients with UVFP, who were candidates for medialization thyroplasty. All the patients were assessed using video stereoscopy to determine the gap and closure of glottis. Voice analysis was also performed. The voice handicap index (VHI) was completed for all the patients. The level of satisfaction with voice quality was also assessed, using the visual analogue scale (VAS).

Results: The mean VHI scores significantly decreased at 1, 3, and 6 months after surgery. The mean VAS scores (for voice quality) significantly increased within 1 month after surgery, whereas they gradually decreased at 5 months after surgery. The mean values of minimum and maximum pitch indices were comparable before and after surgery. The mean jitter score decreased at 1 month after surgery, while it remained constant at 6 months after surgery. The mean shimmer score gradually reduced within 3 months after surgery. On the other hand, the mean harmonic/noise ratio (HN/R) significantly increased at 6 months after surgery. The findings showed a significant decline in the frequency of anterior and posterior glottis gaps at all postoperative intervals.

Conclusions: Short-term improvement of vocal quality and glottic efficiency, along with reduced glottis gap, is expected following medialization thyroplasty type I with cadaveric fascia lata.

Keywords: Medialization Laryngoplasty, Fascia Lata, Vocal Cord Paralysis, Stroboscopy, Voice

1. Background

Unilateral vocal fold paralysis (UVFP) is mainly caused by dysfunction of the vagus nerve or recurrent laryngeal nerve. It commonly manifests with swallowing disability, shortness of breath, and hoarseness (1). The most common etiologies of UVFP include iatrogenic injuries, malignancies with invasion to the vagus nerve or recurrent laryngeal nerve, blunt trauma, and iatrogenic phenomena (2-4).

Medical therapy plays a minor role in the treatment of UVFP, and it is commonly accompanied by surgical treatments (5). Multiple surgical techniques have been introduced for the treatment of UVFP. Some of these techniques are temporary, such as injection of a resorbable material into the affected vocal fold, lateral to the thyroarytenoid

muscle in the paraglottic space (6). This technique, known as medialization of the vocal fold, results in the improvement of vocal quality and restores glottal competence, as well as swallowing function (7).

According to recent reports, temporary vocal fold injection obviates the need for permanent medialization laryngoplasty or thyroplasty in comparison with only conservative management (8). Many injectable materials have been introduced with valuable characteristics, such as biocompatibility, lack of local tissue reaction or fibrosis, low cost, resistance to absorption or migration, and maintenance of viscoelasticity of the vocal cord (9).

Availability of injection materials has provided some advantages, such as use of office-based outpatient settings, patient convenience, avoidance of general anesthesia, cost

effectiveness, and monitoring of voice quality (10). Despite the benefits of vocal fold injection, laryngeal framework surgery remains the gold standard for the treatment of UVFP with favorable long-term outcomes (8). In medialization laryngoplasty, a common surgical approach, the vocal fold is paralyzed using an external approach. However, this procedure is fully invasive and has significant complications, especially if the surgeon is inexperienced (11).

Use of autologous fascia, harvested from the fascia lata, has been shown to be more effective than other materials (eg, autologous fat, collagen, calcium hydroxylapatite, Gelfoam™, and hyaluronic acid), considering its lower metabolic requirements, more stability, and less susceptibility to resorption (12, 13). However, advantages of this material have been less examined in the clinical setting. Therefore, the present study aimed to assess the beneficial effects of medialization thyroplasty (type I) with cadaveric fascia lata on the vocal function of patients with UVFP.

2. Methods

2.1. Study Population

This prospective interventional case series was performed on patients with UVFP, who were candidates for medialization thyroplasty, referred to Rasoul-e-Akram or Firouzgar hospital (tertiary hospitals with 1 year of preoperative waiting) in Tehran, Iran in 2015. The study protocol was approved by the research and ethics committee of Iran University of Medical Sciences, and written informed consents were obtained from the participants.

Eligible participants (aged 30 - 70 years) with idiopathic or iatrogenic UVFP for at least 1 year, without appropriate response to previous medical therapies, were recruited. The exclusion criteria were history of thyroplasty, multiple idiopathic cranial nerve defects, other secondary types of UVFP, and disease duration shorter than 1 year. Initial premedication with proton pump inhibitors was applied for participants with a history of laryngopharyngeal reflux for 3 to 6 months to avoid laryngeal edema and undercorrection. Before surgery, all the patients were interviewed to collect the baseline information, including demographics and medical history.

2.2. Surgical Technique

After local anesthesia (lidocaine 2% with adrenaline 1/100.000) and insertion of shrinkage cottons, impregnated with phenylephrine and tetracaine in each nostril, positioning, prepping, and draping were carried out (prepping from lips to clavicles, leaving the top of head and

face unprepped to permit nonsterile placement and removal of flexible fiberoptic laryngoscope). Local anesthesia was preferred to permit voice assessment intraoperatively and avoid laryngeal distortion, caused by the endotracheal tube.

The inferior and superior edges of the thyroid cartilage, cricoid cartilages, and cricothyroid membrane were identified. A 4-cm incision was made facing the inferior edge of the thyroid cartilage, extending 1 cm beyond the midline of the opposite side. The strap muscles were retracted to expose the entire thyroid cartilage, including the midline. When the thyroid lamina was exposed, its posterior edge was elevated to improve exposure and identify the inferior tubercle of the thyroid cartilage.

The outer perichondrium of the thyroid cartilage was incised in the midline. The proposed cartilage window was marked after the measurements. The superior margin of the window was in the midline between the thyroid notch and inferior margin of the thyroid cartilage; the inferior margin of the window was located 3 mm above and parallel to the inferior margin of the thyroid cartilage. The anterior vertical line of the window was located 8 mm from the midline of thyroid cartilage for males and 6 mm for females. The intended window size was 6 mm × 10 mm.

After additional local anesthesia, selection of window location, and cutting the marked window, the inner perichondrium was circumferentially elevated over approximately 3 mm around the window using a foam elevator. The used allograft membrane (cadaveric fascia lata) was processed from human normal tissues (freeze-dried and gamma-sterilized) with thickness > 0.5 mm and < 1 mm (size, 3 × 6 cm; Danesh Bonyan Co., Iran).

The cadaveric fascia lata strip, soaked in gentamicin solution, was inserted through the window in the thyroid lamina. The fascia lata strip was secured in the ideal position, determined by fiberoptic laryngoscopy. Approximately 1-mm overcorrection of medialization was considered in anticipation of edema resolution. The strip was secured between the paraglottic space and thyroid cartilage. After homeostasis, the outer perichondrium and strap muscles were closed with 3-0 vicryl. Then, the platysma was sutured with 4-0 vicryl and skin with 5-0 nylon. Mupirocin ointment was applied, followed by dressing.

2.3. Assessments

All the patients were hospitalized for 1 night. They were assessed using video stereoscopy with a 70° Karl-Storz lens to determine the gap and closure of glottis before surgery, as well as 1, 3, and 6 months after surgery. Voice analysis was also performed by a single speech pathologist. Voice analysis was performed on a single text, and acoustic parameters, including maximum phonation time (MPT), jit-

ter, shimmer, harmonic/noise ratio (H/NR), and maximum and minimum pitch, were assessed at the specified intervals.

The voice handicap index (VHI) was completed for all the patients. VHI is a scale to quantify the functional, physical, and emotional impacts of a voice disorder on a patient's quality of life. It consists of 30 items, divided into 3 subscales (10 items each). The subscales are "functional", "emotional", and "physical". The score for each item ranges from 0 to 4, with a maximum total score of 120. The higher the score is, the more serious the voice problem is. In this study, the patients completed VHI within approximately 5 minutes. Moreover, the level of satisfaction with voice quality was assessed using the visual analogue scale (VAS).

2.4. Statistical Analysis

The results are presented as mean \pm standard deviation (SD) for quantitative variables and summarized as frequency (percentage) for categorical variables. Changes in the study parameters before and after surgery were assessed using paired t test or Wilcoxon test. For statistical analysis, SPSS version 16.0 for windows (SPSS Inc., Chicago, IL) was used. P value \leq 0.05 was considered statistically significant.

3. Results

Initially, 13 patients were included in the study, three of whom were excluded because of colon cancer development at 6 months after surgery (1 patient) or missing the follow-up (2 patients). Finally, 10 patients (6 men and 4 women) were recruited and assessed (Table 1). The average age of the participants was 46 years (range, 30 - 70 years). Regarding the etiology of UVFP, six were diagnosed with iatrogenic UVFP and 4 with idiopathic UVFP. The involvement was right-sided in 5 patients and left-sided in 5 patients.

The mean VHI score was 73.54 ± 15.53 at baseline, which significantly decreased to 38.69 ± 13.35 at 1 month after surgery, 42.23 ± 12.11 at 3 months after surgery, and 44.54 ± 11.53 at 6 months after surgery. The results indicated lower VHI scores at different intervals after surgery compared to the baseline, although the difference between postoperative intervals was insignificant (Table 2).

The mean VAS score (for voice quality) was 4.46 ± 0.77 at baseline, which increased to 6.77 ± 0.88 at 1 month after surgery; however, the score gradually decreased in the following 5 months (Table 2). The mean MPT score was 2.31 ± 0.42 before surgery, which increased to 4.29 ± 2.11 , 3.82 ± 1.69 , and 3.95 ± 1.71 at 1, 3, and 6 months after surgery, respectively; there was only a significant difference between the baseline and 1 month after surgery.

The mean values of minimum and maximum pitch indices were comparable before and after surgery (Table 2). The mean jitter score was 2.25 ± 2.33 before surgery, which decreased significantly to 0.69 ± 0.61 at 1 month after surgery; however, it remained constant within 6 months after surgery. The mean shimmer score was 10.89 ± 6.84 at baseline, which gradually reduced within 3 months after surgery. Contrarily, the mean H/NR significantly increased from 10.60 ± 7.83 at baseline to 16.17 ± 7.27 , 16.92 ± 6.71 , and 16.42 ± 6.14 at 1, 3, and 6 months after surgery, respectively. Complete and partial anterior glottis gaps were found in 76.9% and 23.1% of patients, respectively.

Complete and partial anterior gap closure reached 76.9% and 15.4% at 1 month after surgery, 76.9% and 15.4% at 3 months after surgery, and 15.4% and 76.9% at 6 months after surgery, respectively, indicating a significant decline at different postoperative intervals, compared to the baseline. Similarly, complete and partial posterior glottis gaps were reported in 84.6% and 15.4% of subjects, respectively. Complete and partial posterior gap closure reached 46.2% and 53.8% at 1 month after surgery, 38.5% and 61.5% at 3 months after surgery, and 23.1% and 76.9% at 6 months after surgery, respectively; the results indicated a gradual reduction in the frequency of this defect within 6 months after surgery.

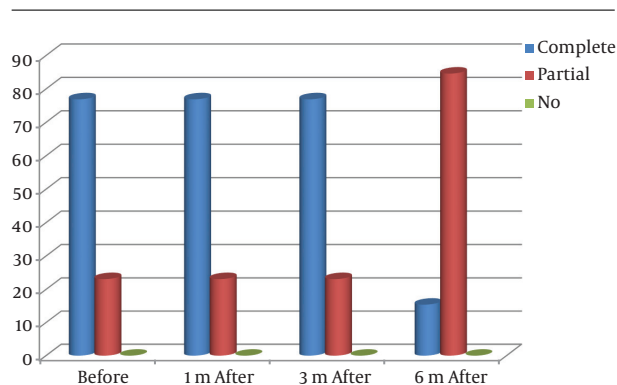


Figure 1. The Percentage of Anterior Glottis Gap Before Surgery and Closure of Anterior Glottis Gap After Surgery

4. Discussion

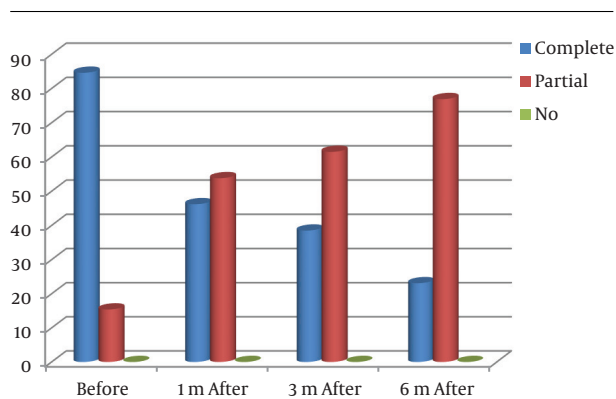
Regarding the effects of medialization thyroplasty on vocal function in patients with UVFP, various injectable materials have been tested; however, there is little evidence on the efficacy of cadaveric fascia lata in the improvement of vocal function. As shown in our study, various functional and qualitative parameters significantly improved

Table 1. Description of the Participants' Characteristics

Number	Gender	Age	Cause of UVCP	Side of UVCP
1	M	32	Iatrogenic (brain surgery for meningioma)	Left
2	M	42	Iatrogenic (glomus jugulare surgery)	Left
3	F	56	Iatrogenic (glomus jugulare surgery)	Left
4	M	30	Idiopathic	Right
5	M	48	Idiopathic	Left
6	M	31	Iatrogenic (true vocal cord polyp surgery)	Right
7	F	54	Iatrogenic (thyroidectomy)	Right
8	M	51	Idiopathic	Right
9	F	70	Idiopathic	Left
10	F	46	Iatrogenic (thyroidectomy)	Right

Table 2. The Study Parameters After Surgery Compared to the Baseline

Parameters	Before Surgery (mean \pm SD)		One Month After Surgery (mean \pm SD)		P Value	Three Months After Surgery (mean \pm SD)		P Value	Six Months After Surgery (mean \pm SD)		P Value
VHI	73.54	15.53	38.69 ^a	13.35	0.001	42.23 ^a	12.11	0.001	44.54 ^a	11.53	0.001
VAS	4.46	0.77	6.77 ^a	0.88	0.01	6.69 ^a	0.63	0.01	5.69 ^a	0.63	0.01
MPT	2.31	0.42	4.29	2.11	0.8	3.82	1.69	0.8	3.95	1.71	0.8
Minimum pitch	152.46	51.27	153.31	44.92	0.6	150.61	44.61	0.6	152.24	48.57	0.6
Maximum pitch	221.679	117.752	205.247	62.697	0.9	205.783	59.565	0.9	212.318	70.615	0.9
Mean pitch	194.931	83.49	185.892	48.73	0.6	185.377	41.51	0.6	188.112	50.67	0.6
Jitter	2.258	2.329	0.697 ^a	0.618	0.03	1.123	1.403	0.2	0.792	0.983	0.2
Shimmer	10.897	6.84	7.766	7.01	0.1	5.603	4.86	0.3	5.855 ^a	4.92	0.3
H/NR	10.601	7.83	16.173 ^a	7.27	0.004	16.925	6.71	0.4	16.415	6.14	0.4

^a P < 0.05.**Figure 2.** The Percentage of Posterior Glottis Gap Before Surgery and Gap Closure After Surgery

with our technique. Medialization thyroplasty with cadaveric fascia lata led to a decline in VHI score (indicating a decline in vocal function-related problems affecting quality of life), an increase in the mean VAS score (indicating an increase in voice quality satisfaction), an increase in MPT

score (indicating an increase in glottic efficiency), and improvement of acoustic parameters.

In addition, the applied procedure led to a significant decline in the anterior glottis gaps. In a similar study by Reijonen et al., most voice parameters significantly improved after injection laryngoplasty with autologous fascia (13). In another study by Rihkanen et al., video analysis revealed fewer large glottal gaps after augmentation with autologous fascia (14). In addition, the maximum gap between the vocal folds decreased from 7.21 to 1.65 units.

Use of autologous fascia dates back to 1998 when the advantages of this technique, including low metabolic requirements, more stability, and less susceptibility to resorption compared to other materials, such as autologous fat and collagen, were described (15).

Although the fascia lata, temporal fascia, rectus abdominis sheath, and aponeurosis of the anterior abdominal wall can be all harvested, fascia lata, especially the cadaveric type, is now the preferred donor site owing to the abundance of tissues and easy access (16). Use of fascia lata can minimize the risk of rejection, allergic reactions,

scarring or fibrosis of the subepithelial space, and infection transmission; moreover, it shows effective results on voice analysis (14, 17, 18). In a study on fascia augmentation of the vocal fold, the mean fascia graft yield in the canine larynx was 33%, which suggests that significant overcorrection may be necessary to produce optimal results; however, their clinical experience did not indicate these trends (17).

4.1. Conclusion

In the present study, although some acoustic and aerodynamic parameters showed significant improvements within 6 months after surgery compared to the baseline, there were slight fluctuations in some other parameters between 3 and 6 months after surgery. Some other parameters, such as minimum and maximum pitch indices, showed no continuous improvement or decline. Regarding early restoration, it is reasonable to evaluate voice quality earlier (within 1 to 3 months). We recommend voice measures after longer periods of surgical treatment to evaluate long-term voice quality. This suggestion is also supported by several other studies (19-22), which showed that voice quality after thyroplasty type I continued to improve in some patients for up to 1 year after surgery. Moreover, long-term animal studies are necessary to clarify these issues and to confirm the success of freeze-dried fascia, which persists without significant shrinkage. Therefore, use of medialization thyroplasty with cadaveric fascia lata can improve vocal function, acoustic parameters, and glottal gaps, and therefore, increase the patients' vocal-related quality of life.

Footnotes

Authors' Contribution: Study concept and design: Farzad Izadi, Hosein Rasoolpanah, and Ehsan Shams Koushki; acquisition of data: Farzad Izadi, Mojtaba Maleki, Aslan Ahmadi, and Ehsan Shams Koushki; drafting of the manuscript: Farzad Izadi and Ehsan Shams Koushki; critical revision of the manuscript for important intellectual content: Farzad Izadi and Mojtaba Maleki; administrative, technical, and material support: Farzad Izadi, Mojtaba Maleki, Ehsan Shams Koushki, Hosein Rasoolpanah, and Somaye Kazemipour; study supervision: Farzad Izadi, Mojtaba Maleki, and Ehsan Shams Koushki.

Financial Disclosure: We have no financial interests related to this manuscript.

References

1. Spataro EA, Grindler DJ, Paniello RC. Etiology and Time to Presentation of Unilateral Vocal Fold Paralysis. *Otolaryngol Head Neck Surg.* 2014;151(2):286-93. doi: [10.1177/0194599814531733](https://doi.org/10.1177/0194599814531733). [PubMed: 24796331].
2. Chen HC, Jen YM, Wang CH, Lee JC, Lin YS. Etiology of vocal cord paralysis. *ORL J Otorhinolaryngol Relat Spec.* 2007;69(3):167-71. doi: [10.1159/000099226](https://doi.org/10.1159/000099226). [PubMed: 17264533].
3. Glazer HS, Aronberg DJ, Lee JK, Sagel SS. Extralaryngeal causes of vocal cord paralysis: CT evaluation. *AJR Am J Roentgenol.* 1983;141(3):527-31. doi: [10.2214/ajr.141.3.527](https://doi.org/10.2214/ajr.141.3.527). [PubMed: 6603763].
4. Laccourreye O, Malinvaud D, Menard M, Bonfils P. [Unilateral laryngeal nerve paralysis in the adult: Epidemiology, symptoms, physiopathology and treatment]. *Presse Med.* 2014;43(4 Pt 1):348-52. doi: [10.1016/j.lpm.2013.07.029](https://doi.org/10.1016/j.lpm.2013.07.029). [PubMed: 24525308].
5. Ko HC, Lee LA, Li HY, Fang TJ. Etiologic features in patients with unilateral vocal fold paralysis in Taiwan. *Chang Gung Med J.* 2009;32(3):290-6. [PubMed: 19527608].
6. Srirompotong S, Sae-Seow P, Srirompotong S. The cause and evaluation of unilateral vocal cord paralysis. *J Med Assoc Thai.* 2001;84(6):855-8. [PubMed: 11556465].
7. Ramadan HH, Wax MK, Avery S. Outcome and changing cause of unilateral vocal cord paralysis. *Otolaryngol Head Neck Surg.* 1998;118(2):199-202.
8. Kwon TK, Buckmire R. Injection laryngoplasty for management of unilateral vocal fold paralysis. *Curr Opin Otolaryngol Head Neck Surg.* 2004;12(6):538-42. [PubMed: 15548914].
9. Misono S, Merati AL. Evidence-based practice: evaluation and management of unilateral vocal fold paralysis. *Otolaryngol Clin North Am.* 2012;45(5):1083-108. doi: [10.1016/j.otc.2012.06.011](https://doi.org/10.1016/j.otc.2012.06.011). [PubMed: 22980687].
10. Siu J, Tam S, Fung K. A comparison of outcomes in interventions for unilateral vocal fold paralysis: A systematic review. *Laryngoscope.* 2016;126(7):1616-24. doi: [10.1002/lary.25739](https://doi.org/10.1002/lary.25739). [PubMed: 26485674].
11. Alghonaim Y, Roskies M, Kost K, Young J. Evaluating the timing of injection laryngoplasty for vocal fold paralysis in an attempt to avoid future type 1 thyroplasty. *J Otolaryngol Head Neck Surg.* 2013;42:24. doi: [10.1186/1916-0216-42-24](https://doi.org/10.1186/1916-0216-42-24). [PubMed: 24499514].
12. Cheng Y, Li ZQ, Huang JZ, Xue F, Jiang MJ, Wu KM, et al. Combination of autologous fascia lata and fat injection into the vocal fold via the cricothyroid gap for unilateral vocal fold paralysis. *Arch Otolaryngol Head Neck Surg.* 2009;135(8):759-63. doi: [10.1001/archoto.2009.91](https://doi.org/10.1001/archoto.2009.91). [PubMed: 19687394].
13. Reijonen P, Tervonen H, Harinen K, Rihkanen H, Aaltonen LM. Long-term results of autologous fascia in unilateral vocal fold paralysis. *Otolaryngol Head Neck Surg.* 2009;126(8):1273-8.
14. Rihkanen H, Reijonen P, Lehtikoinen-Soderlund S, Lauri ER. Videostroboscopic assessment of unilateral vocal fold paralysis after augmentation with autologous fascia. *Eur Arch Otorhinolaryngol.* 2004;261(4):177-83. doi: [10.1007/s00405-003-0642-7](https://doi.org/10.1007/s00405-003-0642-7). [PubMed: 12942240].
15. Rihkanen H. Vocal fold augmentation by injection of autologous fascia. *Laryngoscope.* 1998;108(1 Pt 1):51-4. [PubMed: 9432067].
16. Boyce RG, Nuss DW, Kluka EA. The use of autogenous fat, fascia, and nonvascularized muscle grafts in the head and neck. *Otolaryngol Clin North Am.* 1994;27(1):39-68. [PubMed: 8159427].
17. Duke SG, Salmon J, Blalock PD, Postma GN, Koufman JA. Fascia augmentation of the vocal fold: graft yield in the canine and preliminary clinical experience. *Laryngoscope.* 2001;111(5):759-64. doi: [10.1097/00005537-200105000-00002](https://doi.org/10.1097/00005537-200105000-00002). [PubMed: 11359152].
18. Reijonen P, Lehtikoinen-Soderlund S, Rihkanen H. Results of fascial augmentation in unilateral vocal fold paralysis. *Ann Otol Rhinol Laryngol.* 2002;111(6):523-9. doi: [10.1177/00034894021100608](https://doi.org/10.1177/00034894021100608). [PubMed: 12090708].
19. Lundy DS, Casiano RR, Xue JW, Lu FL. Thyroplasty type I: short-versus long-term results. *Otolaryngol Head Neck Surg.* 2000;122(4):533-6. doi: [10.1067/mhn.2000.102186](https://doi.org/10.1067/mhn.2000.102186). [PubMed: 10740173].

20. Lu FL, Casiano RR, Lundy DS, Xue JW. Longitudinal evaluation of vocal function after thyroplasty type I in the treatment of unilateral vocal paralysis. *Laryngoscope*. 1996;**106**(5 Pt 1):573-7. [PubMed: [8628083](#)].
21. Gray SD, Barkmeier J, Jones D, Titze I, Druker D. Vocal evaluation of thyroplastic surgery in the treatment of unilateral vocal fold paralysis. *Laryngoscope*. 1992;**102**(4):415-21. doi: [10.1288/00005537-199204000-00008](#). [PubMed: [1556891](#)].
22. Netterville JL, Stone RE, Luken ES, Civantos FJ, Ossoff RH. Silastic medialization and arytenoid adduction: the Vanderbilt experience. A review of 116 phonosurgical procedures. *Ann Otol Rhinol Laryngol*. 1993;**102**(6):413-24. doi: [10.1177/000348949310200602](#). [PubMed: [8390215](#)].